

Original Article

Comparison of fiber-reinforced composite crowns and metal ceramic crowns according to attrition of opposing teeth.

Tareq Hassan ^a, A M Aurangjeb ^b

a. Asst. Professor Dept. of Prosthodontics Bangladesh Dental College

b. Asst. Professor and Head Dept. of Dental Public Health MH Samorita Medical College & Dental Unit

ARTICLE INFO

Article history:

Received 08 October 2013

Accepted 15 March 2014

Key words:

Attrition of opposing teeth,
Fiber reinforced Composite crown,
Metal ceramic crown

ABSTRACT

Back ground: Fiber reinforcement was introduced to clinical dentistry for the first time in the 1960s when investigators attempted to reinforce polymethyl- methacrylate dentures with glass or carbon fibers. It has recently been shown that crowns, bridges and posts made of FRC can be used successfully in dental practice and they are esthetically more acceptable than conventional metal ceramic crown.

Aims: A prospective comparative cross-sectional study was performed involving 60 patients who attended in the out patients department of Prosthodontics, Faculty of Dentistry, BSMMU during the period of January 2007 to December 2008.

Objective: Compare fiber-reinforced composite crowns and metal ceramic crowns according to attrition of opposing teeth.

Methods: Clinical data were recorded from the randomly selected 60 patients divided in to tow groups “experimental” and “control”. Attrition of opposing teeth was indexed after California Dental Associations quality evaluation system.

Results: In group A patients, 12(40.0%) were male and 18(60.0%) female. In group B patients 14(46.7%) were male and 16(53.3%) were female. All the patients were in grade I in both groups after 4 months. After 8 months all patients were in grade I in group A and 29(96.7%) patients were in grade I in group B. After 12 months all patients were in grade I in group A and 28(93.3%) patients were in grade I in group B. The difference was not statistically significant ($p>0.05$) in chi square test.

Conclusion: The Fiber Reinforced Composite crown represents a valuable development in field of Prosthetic Dentistry.

*Address of Correspondence:

Dr Tareq Hassan

Email: tareqbipul@gmail.com

Phone: 01711817126

Introduction

Metal–ceramic crowns are clinically successful¹. But the visibility of metal and the change in natural tooth translucency is aesthetically unfavorable. The desire for natural looking restorations has encouraged research in the last

decades on metal-free, tooth colored materials for dental restorations².

As early all-ceramic restorations exhibited high failure rates,³ an alternative has been seen in the use of reinforced composite materials. In recent years, there have been several in vitro⁴⁻⁶ and in vivo studies^{7,8} of the properties of these composites and promising results have been reported for crowns,⁹ and for fixed partial dentures.¹⁰

However, although these materials seem to provide excellent aesthetics,¹¹ some authors do not recommend composite materials for permanent restorations,^{12,13} because of their unstable aesthetics, their increased wear¹⁴ and their liability to plaque accumulation.¹⁵

With the introduction of fiber reinforced composites, it seemed to be possible to eliminate these disadvantages of composites and to exploit their advantages, including the simple laboratory procedure, the lower costs and the possibility of repair.

Additionally, this new generation of composites has given promising in vitro results with respect to color change,¹⁶ wear¹⁷ and fracture resistance.¹⁸

The objective of this present prospective clinical study was then the assessment of the attrition of the opposing teeth due to experimental fiber reinforced composite anterior crowns, compared with a metal-ceramic control group.

Methods

Participants for this study were recruited from patients visiting the Department of Prosthodontics Faculty of Dentistry, BSMMU during the period of January 2007 to December 2008. The university's review board approved the study and all patients signed an informed consent form. Criteria for including was-Fracture teeth with healthy periodontal tissue, Discolored anterior teeth, Endodontic ally treated tooth (Root canal treated tooth), Abrasion, erosion of anterior teeth and excluding- Excluding premolar and molar teeth, Periodontally compromised teeth, Para functional habit (bruxer), Vertical fracture, Grossly damage teeth, Developmentally defective teeth; all evaluated by the examiners.

at chair side and laboratory procedures followed a standardized scheme. After the removal of old restorative materials and caries excavation, the

teeth were built up according to the manufacturer's instructions.

Pre impregnated resin, flat & Unidirectional Dentapreg fiber strip manufactured by Prestige Dental UK was used for fabrication of framework of crown. Bucco-linguallay length of the restoration was measured by scale & Dentapreg fiber strip was cut down according to measurement.

Covering paper of Dentapreg strip was removed and adapted one side of the fiber -reinforced composite (FRC) on the buccal side teeth and visible light (Litex) was applied for 20 seconds. Then the fiber -reinforced composite was shaped and adapted slowly lingual side of the teeth and light curing was applied for 20 seconds. Then the transparent plastic protective film on the strip was removed.

By the incremental way the hybrid veneering composite (ceramic nano-Densply) was applied over the abutments/die and light curing was applied for 40 seconds. The medial and distal proximal contact was made up with the help of cellophane strip. Gingival embrasure was prepared by the application of standard dental wedges. Final light curing, shaping, polishing and finishing were done by standard ways. The fiber Reinforced Composite full veneer crown was polished by standard composite plastic polisher.

The inside of the crown of Fiber Reinforced Composite (FRC) was sand blasted with aluminum oxide. The internal surface was then treated with a bonding agent and delivered with a low viscosity, hybrid, and composite luting agents. These luting agents were bonded to the inside of the crown to the etched dentine and enamel of the abutments.

The tooth reduction was done in all aspect with ideal procedure. Impression was taken with alginate. Cast was poured with die stone. Die was prepared with ideal method and trimming was done for wax pattern. Waxing was done with inlay casting wax. Investing and casting were done with standard procedure. Metal framework was tried in for proper fit. Porcelain was bonded over metal framework. Porcelain bonded prostheses was tried. Final polishing and glazing was done.

Cementation was done with Glass-inomer luting cement.

Instruction was given to the patients and advised them to report after 4 months, 8 months and 12months interval. Attrition of opposing teeth was indexed after California Dental Associations quality evaluation system¹⁹.

Attrition (on the opposite natural tooth):

- **Grade I:** No attrition
- **Grade II:** Mild to moderate attrition
- **Grade III:** Severe attrition

Both the patients and the examiners were blinded to the previous results.

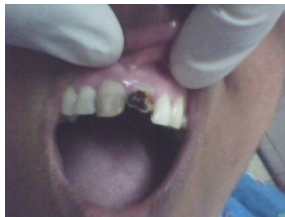

Figure a




figure b



figure c

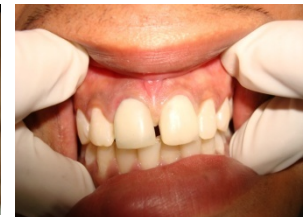

figure d

Data Collection: Necessary data were collected from the patients who attended to report their prostheses condition after 4 months, 8 months and 12 months.

Data analysis: All the relevant collected data was compiled on a master chart first. After coding and editing, the collected data was analyzed by using statistical package for social science (SPSS). The result was presented in tables. Chi-square test was done by using Epi Info (version 12). Results of significance were

expresses as P-value. P-value <0.05 was considered as significance.

Results

The observational study was done after 4 months, 8 months and 12 months interval of the cementation of crowns and data were collected according to selected parameters of esthetic status of opposing teeth. Collected data of different parameters was presented in tabulated form and statistical analysis was done to observe the statistical significance.

Table I: Distribution of patients by age (n=60).

Age (year)	Group A (n=30)		Group B (n=30)	
	n	%	n	%
≤20	6	20.0	6	20.0
21 – 30	18	60.0	19	63.3
31 – 40	5	16.7	5	16.7
> 40	1	3.3	0	0.0
Mean ±SD	24.9	±5.8	25.0	±4.8

Group A - fiber Reinforced Composite crown,

Group B - Metal ceramic composite crown

n = number of subjects

The table shows the age distribution of both groups patients of the study. The age of patients ranged between 18 and 42 years in group A and 17 and 38 years in group B. The highest number of patients was in the age group 21-30 years in

both groups. The mean age was 24.9±5.8 years and 25.0±4.8 years in group A and group B respectively.

Table II: Distribution of patients by sex (n=60).

Sex	Group A (n=30)		Group B (n=30)		p value
	n	%	n	%	
Male	12	40.0	14	46.7	0.602 ^{NS}
Female	18	60.0	16	53.3	

Statistical analysis was done by chi square test

NS = not significant

In this study, both male and female patients were treated in both groups. There were 26 male and 34 female patients in the study groups and male female ratio was 1:1.3. In group A patients, 12(40.0%) were male and 18(60.0%) female. In

group B patients 14(46.7%) were male and 16(53.3%) were female. The difference was not statistically significant ($p>0.05$) in chi square test.

Table III: Distribution of patients according to attrition of opposing teeth (n=60) after 4 months.

Attrition of opposing Teeth	Group A (n=30)		Group B (n=30)		p value
	n	%	n	%	
Grade – I	30	100	30	100	-
Grade – II	0	0.0	0	0.0	
Grade – III	0	0.0	0	0.0	

Statistical analysis was done by chi square test

Group A= Fibre reinforced composite crown

Group B= Metal ceramic crown

n= number of subjects

S= significant

Grade I: No attrition

Grade II: Mild to moderate attrition

Grade III: Severe attrition

The table III shows the distribution of patients according to the status of attrition of opposing teeth. All the patients were in grade I in both groups after 4 months.

Table IV: Distribution of patients according to attrition of opposing teeth (n=60) after 8 months.

Attrition of opposing Teeth	Group A (n=30)		Group B (n=30)		p value
	n	%	n	%	
Grade – I	30	100	29	96.7	0.500 ^{NS}
Grade – II	0	0.0	1	3.3	
Grade – III	0	0.0	0	0.0	

Statistical analysis was done by chi square test

Group A= Fibre reinforced composite crown

Group B= Metal ceramic crown

n= number of subjects

S= significant

Grade I: No attrition

Grade II: Mild to moderate attrition

Grade III: Severe attrition

The table IV shows the distribution of patients according to the status of attrition of opposing teeth. After 8 months all patients were in grade I

in group A and 29(96.7%) patients were in grade I in group B. The difference was not statistically significant ($p>0.05$) in chi square test.

Table V: Distribution of patients according to attrition of opposing teeth (n=60) after 12 months.

Grade – I	30	100	28	93.3	
Grade – II	0	0.0	2	6.7	0.246 ^{NS}
Grade – III	0	0.0	0	0.0	

Statistical analysis was done by chi square test

Group A= Fibre reinforced composite crown

Group B= Metal ceramic crown

n= number of subjects

S= significant

Grade I: No attrition

Grade II: Mild to moderate attrition

Grade III: Severe attrition

The table V shows the distribution of patients according to the status of attrition of opposing teeth. After 12 months all patients were in grade I in group A and 28(93.3%) patients were in grade I in group B. The difference was not statistically significant ($p>0.05$) in chi square test.

Discussion

In case of attrition of opposing teeth, after 4 months all the patients of both groups were in grade- I i.e.no attrition. After 8 months, all the patients were in grade-I in group-A. On the other hand, in group-B 29(96.7%) patients were in grade-I and 1(3.3%) patient was in grade-II i.e.mild to moderat attrition. After 12 months all the patients were in grade-I in group-A. In group-B 28(93.3%) patients were in grade-I and 2(6.7%) patients were in grade-II. The percentage of attrition of opposing natural teeth of metal ceramic crown was higher than Fiber Reinforced Composite crown. The difference was not statistically significant ($p>0.05$) in chi square test.

Previous study²⁰ on effect of Fiber reinforced composite in fixed partial denture (FPD) was conducted in the Department of Prosthodontics at

BSMMU, among forty patients divided into two groups. In that study it was showed that there were no change in esthetic status and no attrition of opposing teeth. Only 2(10.0%) patients were found to chip out composites. Fiber reinforced composite fixed partial denture is an innovative alternative to conventional metal ceramic fixed partial denture (Abu Tayeb MD.Ahsan ullah, 2007).

Conclusion

The Fiber Reinforced Composite crown represents a valuable development in field of Prosthetic Dentistry. This study indicates Fiber reinforced composite crown provides life like esthetical appearance, better fracture resistance, good marginal adaptation and no attrition of opposing teeth. As well as it is a time saving restoration, easy to repair and cost effective.

Recommendations

Within the limitations of this study it is strongly recommended that Dentists can use Fiber Reinforced Composite crown to ensure esthetically pleasant and durable restorations.

The following recommendations are put forward for the establishment of the procedure:

- The study should be conducted on a long term basis. A larger period of observations is required to test the hypothesis.
- As it is a technique sensitive restoration so proper curing and high strength

composites should be used to increase the longevity of the prostheses.

- c) The study conducted only at BSMMU among the small group of patients, the additional study with large sample size should be done for further conclusion of this result.

References

1. Donovan T, Simons RJ, Guertin G, Tucker RV. Retrospective clinical evaluation of 1314 cast gold restorations in service from 1 to 52 years. *Journal of Esthetic and Restorative Dentistry* 2004;16:194–204.
2. Ohlmann B, Dreyhaupt J, Schmitter M, Gabbert O, Hassel A, Rammelsberg P. Clinical performance of posterior metal-free polymer crowns with and without fiber reinforcement
One-year results of a randomised clinical trial, *Journal of dentistry* 2006;6:6-11
3. El-Mowafy O, Brochu JF. Longevity and clinical performance of IPS-Empress ceramic restorations — a literature reviews. *Journal of Canadian Dental Association* 2002;68:233–7.
4. Behr M, Rosentritt M, Lang R, Handel G. Flexural properties of fiber reinforced composite using a vacuum/pressure or a manual adaptation manufacturing process. *Journal of Dentistry* 2000;28:509–14.
5. Tezvergil A, Lassila LV, Vallittu PK. The effect of fiber orientation on the polymerization shrinkage strain of fiberreinforced composites. *Dental Materials* 2005;17:17.
6. Bouillaguet S, Schutt A, Alander P, Schwaller P, Buerki G, Michler J, et al. Hydrothermal and mechanical stresses degrade fiber–matrix interfacial bond strength in dental fiber-reinforced composites. *Journal of Biomedical Materials Research Part B Applied Biomaterials* 2006;76:98–105.
7. Gohring TN, Schmidlin PR, Lutz F. Two-year clinical and SEM evaluation of glass-fiber-reinforced inlay fixed partial dentures. *American Journal of Dentistry* 2002;15:35–40.
8. Vallittu PK, Sevelius C. Resin-bonded, glass fiber-reinforced composite fixed partial dentures: a clinical study. *Journal of Prosthetic Dentistry* 2000;84:413–8.
9. Ellakwa A, Thomas GD, Shortall AC, Marquis PM, Burke FJ. Fracture resistance of fiber-reinforced composite crown restorations. *American Journal of Dentistry* 2003;16:375–80.
10. Freilich MA, Meiers JC, Duncan JP, Eckrote KA, Goldberg AJ. Clinical evaluation of fiber-reinforced fixed bridges. *Journal of American Dental Association* 2002;133:1524–34.
11. Cho L, Song H, Koak J, Heo S. Marginal accuracy and fracture strength of ceromer/fiber-reinforced composite crowns: effect of variations in preparation design. *Journal of Prosthetic Dentistry* 2002;88:388–95.
12. Behr M, Rosentritt M, Handel G. Fiber-reinforced composite crowns and FPDs: a clinical report. *International Journal of Prosthodontics* 2003;16:239–43.
13. Bohlsen F, Kern M. Clinical outcome of glass-fiberreinforced crowns and fixed partial dentures: a 3-year retrospective study. *Quintessence International* 2003;34:493–6.
14. Kern M, Strub JR, Lu XY. Wear of composite resin veneering materials in a dual-axis chewing simulator. *Journal of Oral Rehabilitation* 1999;26:372–8.
15. Behr M, Rosentritt M, Latzel D, Handel G. Fracture resistance of fiber-reinforced vs. non-fiber-reinforced composite molar crowns. *Clinical Oral Investigation* 2003;7:135–9.
16. Douglas RD. Color stability of new-generation indirect resins for prosthodontic application. *Journal of Prosthetic Dentistry* 2000;83:166–70.
17. Suzuki S, Nagai E, Taira Y, Minesaki Y. In vitro wear of indirect composite restoratives. *Journal of Prosthetic Dentistry* 2002;88:431–6.
18. Ku CW, Park SW, Yang HS. Comparison of the fracture strengths of metal–ceramic crowns and three ceromer crowns. *Journal of Prosthetic Dentistry* 2002;88:170–5.
19. Clinical Trial Results', *Journal of the California Dental Association*. 1–5
21. Ullah ATA, (2007), “Study on effect of fiber reinforced composite in fixed partial.”