

Case Report

Management of Juvenile Temporo-mandibular Joint Ankylosis by Gap Arthroplasty

*S. Mahmud Mishu,^a Md. Nazmul Hasan,^b Ali Hossain,^c Shahiqul Jabbar^d

- a. Lecturer, Department of Orthodontics & Dentofacial Orthopedics, Update Dental College & Hospital, Dhaka.
b. Assistant Professor & Head, Department of Orthodontics & Dentofacial Orthopedics, Update Dental College & Hospital, Dhaka.
c. Head, Dept of Oral & Maxillofacial Surgery, Chittagong International Dental College Hospital, Chittagong.
d. Assistant Professor & Head, Dept. Of Orthodontics, Chittagong International Dental College Hospital, Chittagong.
-

ARTICLE INFO

Article history:

Received 13 July 2013

Accepted 15 November 2013

Key words:

TMJ disorder,
TMJ Ankylosis,
Gap arthroplasty,

ABSTRACT

Bony ankylosis of the temporomandibular joint (TMJ) in a male patient was not diagnosed until the patient reached his early teens, at which time the condition was treated with a costochondral graft. At the time of treatment, there was an expectation that further orthognathic surgery would be required to correct the skeletal deformity. However, with the release of the ankylosis and growth of the costochondral graft, a good functional and esthetic result was achieved without further surgery. It is important that family dentists be aware of the clinical signs and symptoms of TMJ ankylosis, to allow early diagnosis and treatment.

Introduction

Ankylosis of the Temporo-Mandibular Joint (TMJ) usually refers as fusion of the mandibular condyle to the base of the skull.¹ In a child, it can have devastating effects on the future growth and development of the jaws and teeth. Furthermore, in many cases it has a profoundly negative influence on the psychosocial development of the patient, because of the obvious facial deformity, which worsens with growth.²

Trauma and infection are the leading causes of ankylosis.³ However, in a young patient, a joint injury may not be noticed immediately. The first sign of a significant problem may be increasing limitation of jaw opening, usually noticed by the dentist.⁴ Pain is uncommon. Early diagnosis and treatment are crucial if the worst sequelae of this condition are to be avoided. Optimal results can be achieved only after a complete assessment and development of a long-term treatment plan. We present a case report of TMJ ankylosis diagnosed and successfully treated in the early teen years.^{3,4}

*Address of the correspondence:

Dr. S. Mahmud Mishu

lecturer, Department of orthodontics & Dentofacial Orthopedics,

Update Dental College & Hospital, Turag Dhaka 1711.

Phone: +8801676931751;

e-mail: libertine.mishu@gmail.com

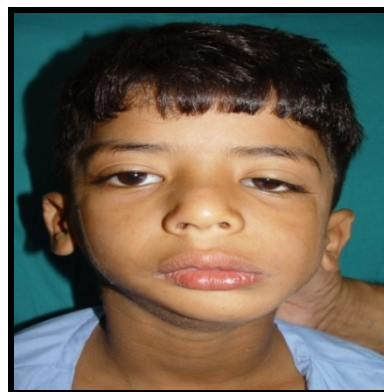Report of the case:

A 12-year-old boy was reported to a private dental practices with complain of restricted mouth opening. At initial presentation, his height was 138 cm (smaller than normal for his age) and his weight 27.1 kg (below the fifth percentile for his age group). He was otherwise healthy. No complications had been reported at birth, and there was no subsequent history of trauma to the facial skeleton. The initial clinical examination revealed an obviously hypoplastic mandible with a class II dental relationship. The mandibular midline was 5cm to the right of the facial midline, and the occlusal plane was canted, maximum opening was minimal, and there was no palpable movement over the right TMJ and only slight rotation on the left side. [Figure 1: A, B & C]

Radiographic investigation included Otrthoentomogram (OPG), lateral cephalometric radiography and 3-dimensional computed tomographic scan [Figure 2: A&B]. These radiographic images confirm bony ankylosis of the right TMJ with bilateral elongation of coronoid process.

Three stage treatment plan were developed including maxillofacial surgery followed by physiotherapy and orthodontic correction by functional appliances. The surgical plane was designed as Gap-arthoplasty through sub-mandibular or pre-auricular approach, with costo-chondral graft and regid internal fixation. Extraction of selected dentition was also planned for. The initial surgery was accomplished under general anesthesia. Right gap arthroplasty & coronoidectomy were performed through the sub-mandibular approach. During the procedure, the surgeon noticed an increase in maximum opening to about 20mm, but interference from the contralateral side prevented further improvement. Therefore, left coronoidectomy

and extraction of teeth 38, 63, 64 (FDI notation) were performed. These procedure allowed the maximum opening to increase to 35 mm. Alginate impression were taken intra operatively to fabricate a splint that would allow a right posterior open bite. It was hoped that adjustment of the splint would help to level the occlusal cant. The splint was secured by means of skeletal fixation. The right temporal bone in the region of the ankylosis was contoured with a bur into a glenoid fossa. The CCG was sculpted to fit this fossa, care being taken not to separate the cartilaginous part of the graft from the bone & was secured to the right ramus with 3 bi cortical screw. Maxillo-mandibular fixation was maintained for 3days & the patient was discharged from hospital 4days after surgery with good range of motion. He started an exercise program involving the use of tongue blades to stretch the mouth maximally, because CPM could not be used with the splint in place. The splint, held in place by circum-mandibular wires, was removed under general anesthesia 8 weeks after the initial surgery. The patient was been referred to orthodontic department then.



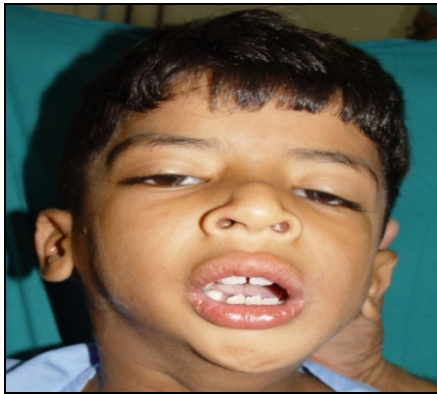
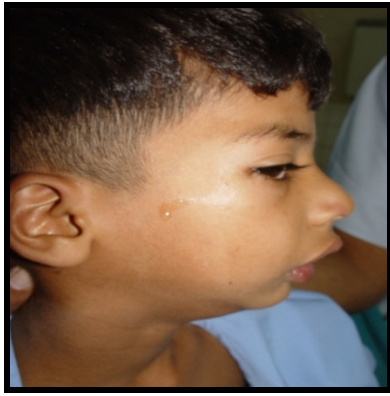
Figure 1: Pre-treatment extra-oral photograph of the patients shows hypo-plastic right mandible in front view (A), under developed mandible in lateral view (B), and limited mouth opening (C).

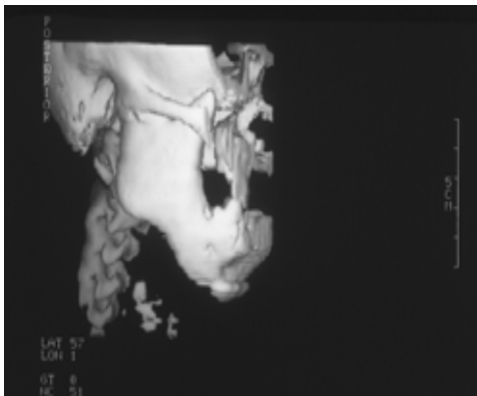
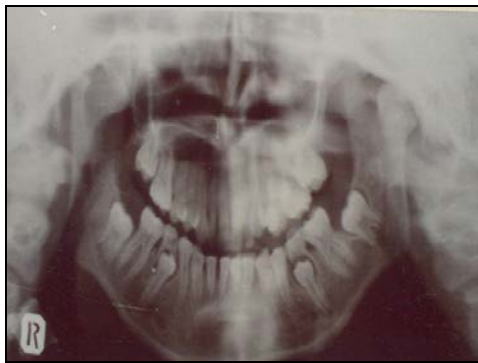

Figure 2: Pre-treatment extra-oral Orthopantomogram(OPG) radiograph (A) and 3D Computed tomogram (B) of the patients shows hypo-plastic right mandible with limited mouth opening.

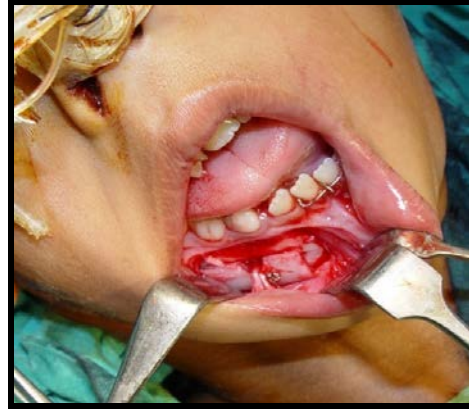
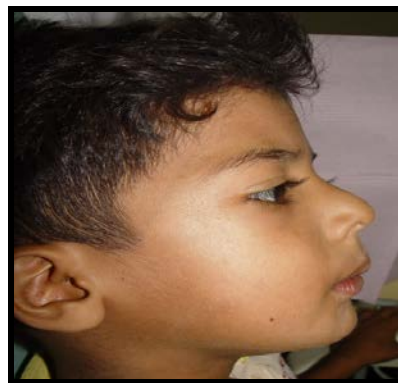
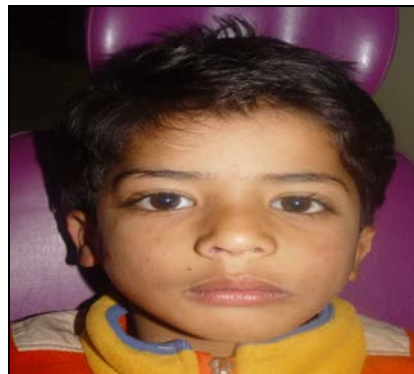Figure 3: Surgical fixation by using intraoral bi-cortical screw.



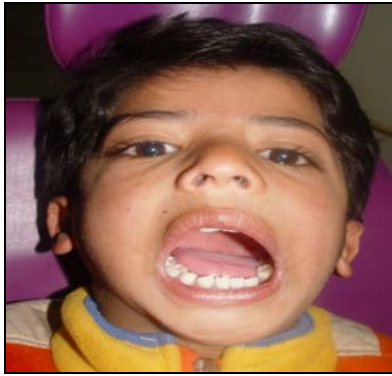

Figure 4: Post-treatment extra-oral photograph of the patients shows bilateral symmetrical right and left mandible in front view (A), normal mandible and face profile in lateral view (B), and adequate mouth opening (C).

Twin block therapy (at the near maximum protrusive position) was started 3 months after the initial surgery. At that time, the vertical opening was about 25mm. The twin-block appliance was worn intermittently (mainly during the evening and at night) for the next year. The range of motion was expected to increase vertically 35 mm by 36 months. Fixed appliance is about to place about 36 months after the initial surgery. Retainers were placed in both arches.

Discussion:

The causes and treatment of TMJ ankylosis have been well documented,^{2,3} with trauma and infection identified as the 2 leading causes.¹ In children, TMJ ankylosis can result in mandibular retro-gnathism with attendant esthetic and functional deficits. Therefore, treatment should be initiated as soon as the condition is recognized, with the main objective of re-establishing joint function and harmonious jaw function.^{4,5} Various autogenous grafts, including the metatarsus,⁶ clavicle,⁷ and iliac crest,⁸ as well as various alloplastic materials,⁹ have been used to reconstruct the TMJ. However, the free CCG has gained popularity in the past 2 decades^{4,9-12}

.Mandibular hypo-mobility resulting from TMJ ankylosis is classified according to location (intracapsular or extracapsular), type of tissue involved (bony, fibrous or fibroosseous) and extent of fusion (complete or incomplete).¹³ If the cause is trauma, it is hypothesized that intra-articular hematoma, along with scarring and formation of excessive bone, leads to the hypomobility. Infection of the TMJ most commonly occurs secondary to contiguous spread from otitis media or mastoiditis, but it may also result from hematogenous spread of infectious conditions such as tuberculosis, gonorrhea or scarlet fever. Systemic causes of TMJ ankylosis include ankylosing spondylitis, rheumatoid arthritis and psoriasis.¹⁴ In children, not only can trauma to the TMJ result in ankylosis, but it may also impair mandibular growth and result in mandibular retrognathism. These problems have functional and esthetic implications, as well as causing difficulties pertaining to nutrition and oral hygiene.¹⁵ A variety of techniques for the treatment of TMJ ankylosis have been described, including intraoral coronoidectomy, ramus osteotomy, high condylectomy, forceful opening of the jaw under general anesthesia, lysis of adhesions of the pterygoid space during exploration for a foreign body,¹⁶ autogenous CCG¹⁷ and free vascularized wholejoint transplants.¹⁸ In addition, several prosthetic options for TMJ reconstruction exist, including Silastic sheeting material (Vitek Inc., Houston, Texas), the TMJ condylar prosthesis, custom glenoid fossa implants, articular eminence implants and mandibular reconstruction plates with condylar heads.¹⁹ The CCG offers several advantages, including biologic and anatomic similarity to the mandibular condyle, low morbidity of the donor site, ease in obtaining and adapting the graft, and regenerative potential in the growing child.^{5,8} When a CCG is used, the hope is that,

because of the similarities of its primary and secondary cartilage to those of the mandibular condyle,⁸ the graft will provide growth potential and keep pace with the growth of the unaffected side, to maintain mandibular symmetry throughout the growth period.⁵ It has been demonstrated that CCGs tend to have a more vertically directed condylar growth pattern and a more laterally positioned condyle than the native bone tissue and may even cause mandibular prognathism necessitating orthognathic surgery in the form of mandibular setback.

This case demonstrates (in support of other similar studies) that use of a CCG to reconstruct a TMJ affected by ankylosis yields a functional condyle with growth potential. In this patient, there has been a significant improvement in the anteroposterior position of the mandible and a noticeable increase in the patient's size since the release of the ankylosis. The net result has been a high degree of patient satisfactory rehabilitation.

References

1. Straith CL, Lewis JR. Ankylosis of the temporomandibular joint. *Plast Reconstr Surg* 1948; 3:464-6.
2. Miller GA, Page HL Jr, Griffith CR. Temporomandibular joint ankylosis: review of the literature and report of 2 cases of bilateral involvement. *J Oral Surg* 1975; 33(10):792-803.
3. Topazian RG. Etiology of ankylosis of the temporomandibular joint: analysis of 44 cases. *J Oral Surg* 1964; 22:227-33.
4. Kaban LB, Perrott DH, Fisher K. A protocol for management of temporomandibular joint ankylosis. *J Oral Maxillofac Surg* 1990; 48(11): 1145-51; discussion 1152.
5. Guyuron B, Lasa CI Jr. Unpredictable growth pattern of costochondral graft. *Plast Reconstr Surg* 1992; 90(5):880-6; discussion 887-9.
6. Dingman RO. Reconstruction of both mandibular condyles with metatarsal bone grafts. *Plast Reconstr Surg* 1971; 47(6):594-9.
7. Snyder CC, Levine GA, Dingham DL. Trial of sternoclavicular whole joint graft as a substitute for the temporomandibular joint. *Plast Reconstr Surg* 1971; 48(5):447-52.
8. Figueroa AA, Gans BJ, Pruzansky S. Long-term follow-up of mandibular costochondral graft. *Oral Surg Oral Med Oral Pathol* 1984; 58(3):257-68.
9. Huang CS, Ross RB. Surgical advancement of the retrognathic mandible in growing children. *Am J Orthod* 1982; 82(2):89-103.
10. Link JO, Hoffman DC, Laskin DM. Hyperplasia of a costochondral graft in an adult. *J Oral Maxillofac Surg* 1993; 51(12):1392-4.
11. Munro IR, Chen YR, Park BY. Simultaneous total correction of TMJ ankylosis and facial asymmetry. *Plast Reconstr Surg* 1986; 77(4):517-29.
12. Ko EW, Huang CS, Chen YR. Temporomandibular joint reconstruction in children using costochondral grafts. *J Oral Maxillofac Surg* 1999; 57(7):789-98; discussion 799-800.
13. Rowe NL. Ankylosis of the temporomandibular joint. Part 3. *J R Coll Surg Edinb* 1982; 27(4):209-18.
14. Fonseca RJ. *Oral and Maxillofacial Surgery: Temporomandibular Disorders*. Philadelphia (PA): W.B. Saunders Company; 2000. p. 309-13.
15. Westermark AH, Sindet-Pedersen SS, Boyne PJ. Bony ankylosis of the temporomandibular joint: case report of a child treated with Delrin Condylar implants. *J Oral Maxillofac Surg* 1990; 48(8):861-5.
16. Guralnick WC, Kaban LB. Surgical treatment of mandibular hypomobility. *J Oral Surg* 1976; 34(4):343-8.
17. MacIntosh RB, Henry FA. A spectrum of application of autogenous costochondral grafts. *J Maxillofacial Surg* 1977; 5(4):257-67.
18. Dattilo DJ, Granick MS, Soteranos GS. Free vascularized whole joint transplant for reconstruction of the temporomandibular joint: a preliminary case report. *J Oral Maxillofac Surg* 1986; 44(3):227-9.
19. Moriconi ES, Popowich LD, Guernsey LH. Alloplastic reconstruction of the temporomandibular joint. *Dent Clin North Am* 1986; 30(2): 307-25.