

## Case Study

---

# “Progressive idiopathic external root resorption in multiple teeth: A 6-year follow-up study)

\*Shirin Sultana Chowdhury<sup>1</sup>, AKM Bashar<sup>2</sup>

1. Associate professor, Department of Conservative Dentistry and Endodontics, Update Dental College, Dhaka.
  2. Associate professor, Department of Conservative Dentistry and Endodontics, Faculty of Dentistry, BSM Medical University, Dhaka.
- 

### ARTICLE INFO

---

#### Article history:

Received: 14 July 2014

Accepted: 28 August 2014

---

#### Key words:

Progressive, Idiopathic, resorption

---

### Abstracts:

---

This paper describes a case of progressive idiopathic external root resorption at cement-enamel junction in multiple teeth of both jaws ongoing for 6 years. In addition to clinical features serial radiographs are presented that revealed progressive involvement of root resorption. Since the first appointment until the next 6 years no clinical, radiographic or laboratory findings were available to disclose the etiology of such extensive ongoing resorption; neither the provided treatments could arrest the progression of the pathology that forced the clinicians to diagnose the case as progressive idiopathic external resorption.

### Introduction:

External root resorption of the roots of permanent teeth commonly occurs due to chronic periodontal or periapical infections, orthodontic therapy, eruption of the underlying permanent dentition, benign and malignant neoplasms, Paget's disease of bone, and/or trauma to the jaws. When none of these causes are present, resorption of teeth is termed "idiopathic resorption of teeth."<sup>1,2</sup>

---

The process of root resorption involves a complex interaction of inflammatory cells, resorbing cells, hard tissue, cytokines and enzymes such as collagenase, matrix metalloproteinase and cysteine proteinase.<sup>3,4</sup> The periodontal ligament is a specialized connective tissue which acts as a barrier between the alveolar bone and cementum.<sup>5</sup> Localized damage or loss of periodontal ligament renders the denuded cementum surface chemotactic to clastic cells such as osteoclasts, macrophages and monocytes.<sup>2,4,6-8</sup> This can result in root resorption. In cases where multiple teeth are involved, Loe and Waerhaug<sup>9</sup> have suggested that the dental tissues become part of the osseous system and thus subject to remodeling.

External root resorption affects either or both apical and cervical regions of one or several teeth, but most commonly occurs in the apical region. It is relatively rare to find idiopathic resorption in the cervical areas of the tooth and even more uncommon for the condition to involve multiple teeth.<sup>2</sup>

#### \*Address of Correspondence:

**Dr. Shirin Sultana Chowdhury**

Associate Professor, Dept. of Conservative Dentistry & Endodontics

Update Dental College, Turag, Dhaka-1711

Phone: 01716-435598

Email: shumii177nnn@gmail.com

In the present paper, we report 6 year's sequential clinical and radiographic presentation of a rare progressive idiopathic cervical root resorption in multiple teeth of both jaws. In absence of available clues for diagnosis, failure in respect of arresting progression of the disease after intervention render the case to conclude as idiopathic multiple external (cervical) root resorption; which is a rare entity.

### Case report:

The 37-year-old Bangladesi male patient was first seen by February'2005 when he was referred to the department of Conservative Dentistry and Endodontics, BSMMU for chewing difficulty and continuous low grade dull pain at the anterior segment of right lower jaw for last 2 months along with radiologic evidence of radiolucency with poorly defined borders in the cervical third of the root on teeth no 31,41,42,43 and 48. He is a farmer, not well off and hails from a remote area of Bangladesh where transportation facilities are not well enough for getting a regular basis routine treatment.

Patient gave a history of similar complain at the posterior segment of the lower right side for last 2 years for which he had been undergone a serial extractions of multiple teeth without confirming any diagnosis. He had no familial history relating the pathology neither his deciduous dentition was affected. There was no history of trauma or orthodontic treatment.

On examination, extra oral appearance was symmetrical with no regional lymph node enlargement. Multiple missing teeth were found in the lower right mandible due to previous extraction; all other teeth including the symptomatic three teeth (tooth no 41, 43 & 48) were of normal morphology and color with no carious involvement and fracture. An acceptable level of oral hygiene was found other than a slight change in complexion around the symptomatic teeth (tooth no 41, 43 & 48) and 4mm, 3mm, 4mm periodontal pocket observed in tooth number 41, 43 and 48 consecutively. All the symptomatic teeth showed a brief exaggerated response than other asymptomatic teeth in thermal vitality test. On radiologic examination, radiolucent area with poorly defined borders found in the

cervical third of the root on teeth no 31,41,42,43 and 48. [Figure 1].

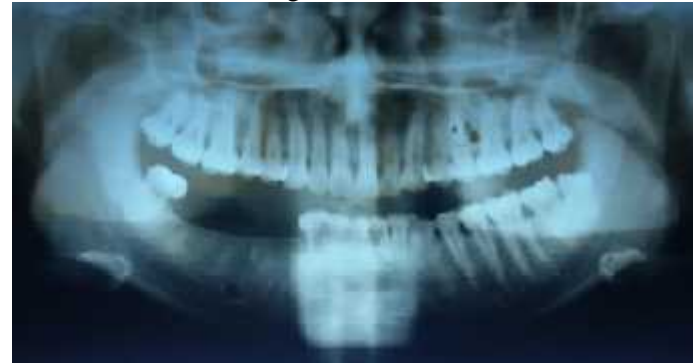

Figure 1: OPG showing radiolucent area with poorly defined borders found in the cervical third of the root on teeth no 31,41,42,43 and 48.

Patient was advised for routine haematological tests including alkaline phosphatase, serum calcium, total urine phosphate; all of which found within normal level. Serum calcium was 9.9mg/100ml (normal range 8.1-10.9mg/100ml) serum alkaline phosphatase was 100U/L (normal range, upto 644U/L) and total urine phosphate level was 29.9mg/day (normal 400-1300mg/day). Hormone assay (T<sub>3</sub>, T<sub>4</sub>, TSH, Parathormone) also did not reveal any positive findings. In absence of any positive findings other than periodontal pocket formation and radiological sign of cervical resorption in tooth no 31,41,42, 43 and 48 we provisionally diagnose the case as external cervical root resorption with D/D of internal resorption.

Teeth no 31,41,42, and 43 was extracted due to extensive destruction by resorptive process and curette of periodontal pocket around teeth no. 48 was carried out preliminarily. Histopathology of the curetted cervical soft tissue showed hyperkeratosis, parakeratosis, mild acanthosis and mild dysplastic changes in lining epithelium. There was mild infiltration of chronic inflammatory cells in subepithelial region. A removable partial denture for the missing teeth due to extraction was provided to the patient after proper healing for rehabilitation. Oral hygiene instruction described and demonstrated; that the patient was advised to maintain strictly.

He was scheduled to follow up after every three month but his economical condition and remote location prevented him to do so. Finally after 1year, when the patient returned

on a recall visit, he came with a same complain of low grade pain at the right maxillary posterior segment. Recall radiograph revealed further advancement in the progression of the lesion on tooth no 48 and newly developed large radiolucent area having irregular outline in the cervical area on tooth no 14,15, 16, 17.(Fig 2)

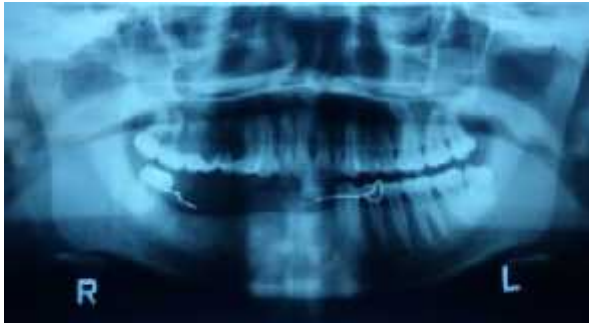


Figure 2: OPG showing further advancement in the progression of the lesion on tooth no 48 and newly developed large radiolucent area having irregular outline in the cervical area on tooth no 14,15, 16, 17.

Considering that the pathology may be an internal resorption, root canal treatment advised for tooth no. 48 to arrest the progression of the resorptive lesion; while because of the extensive destruction, extraction was advised for tooth no 15, 16 & 17. Patient's urgency rendered to dispose him without any treatment this time. When the patient came back again after 2 more years, we found progression of the resorptive lesion already involved and extended from tooth no 11 upto 18. (Fig 3)

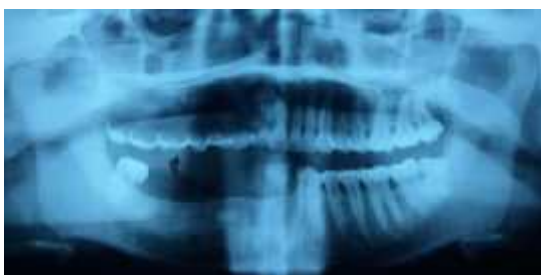

Figure 3: Radiograph showing progression of the resorptive lesion already involved and extended from tooth no 11 upto 18.

Root canal treatment done on tooth no 11and 48 this time; (fig 4). Extraction advised for tooth no 12, 13, 14, 15, 16, 17 and 18; those

carried out ultimately. It should be mentioned that the patient's oral hygiene was good enough throughout the follow up period.

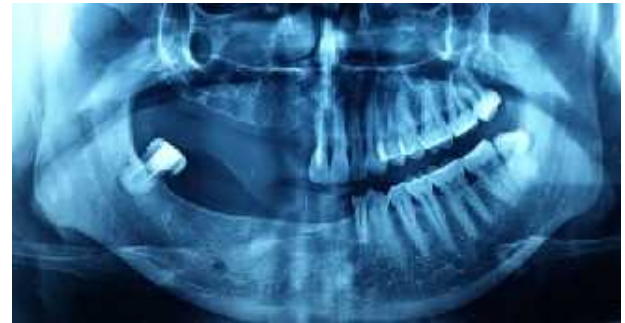

Figure 4: Radiograph showing evidence of root canal treatment on tooth no 11 and 48

During extraction of tooth no. 12 to 18, curettage of the alveolar bone by flap surgery done and excised tissues were sent for histopathology. The report revealed only nonspecific inflammation. Profuse chronic inflammatory cells with very few clastic cells seen histologically.

A new progression of resorption like pathology in the form of cervical radiolucency seen in tooth no 21,23 and 27. (fig 5) During follow-up for last 6 years, there were evidences of ongoing resorption of teeth no. 48 and 11, which were root treated (Figure 5&6).

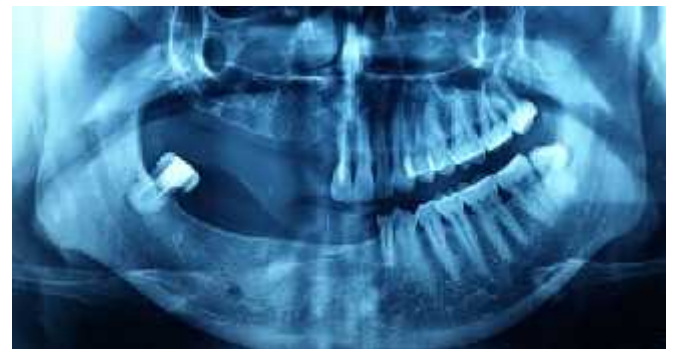

Figure 5: new progression of resorption like pathology in the form of cervical radiolucency seen in tooth no 21,23 and 27.

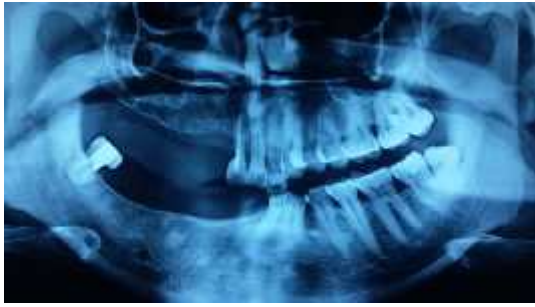

Figure 6: Radiograph showing progression of resorption even after root canal treatment on 48 and 11.

Throughout the total follow up period of 6 years, there was no positive clue for diagnosing the case. But, the nature of destruction as seen clinically and mostly by sequential radiograph (OPG) that showed radiolucency with poorly defined borders in the cervical third of the root from one tooth to other and one jaw to the another in a progressive way even crossing the midline also. So we rather want to say that this is a case of progressive idiopathic cervical/external root resorption.

### Discussions:

Multiple external resorption of permanent teeth is an uncommonly reported phenomenon. Idiopathic root resorption may affect a single tooth or multiple teeth originating from cement-enamel junction. A single tooth is most commonly affected. Stafne and Slocumb<sup>10</sup> reported that only 19 of 179 cases of idiopathic resorption involved more than 1 tooth; 2 teeth were involved in 17 cases and 3 teeth were affected in 2 cases. Although multiple root resorption is rare, some studies regarding this pathology are mentioned. Mueller and Rony<sup>4</sup> reported the first case of idiopathic cervical root resorption in 1930; since then, several cases have been reported<sup>1-3, 5-13</sup>. In 1979, Hopkins and Adams<sup>14</sup> presented the case where maxillary teeth are severely affected and within 3 years all remaining teeth of both jaws were extracted because of severe resorptive process. There was no history of trauma as well as carious involvement. In 1989 Lydiatt et al<sup>15</sup> reported the case with multiple idiopathic root resorption that eventually affected all maxillary teeth. Recently, Liang et al<sup>2</sup> reviewed the literature on multiple idiopathic cervical root resorption. They found that all cases were asymptomatic and usually discovered as an incidental finding on

radiographic examination. This case was presented with chewing problem and history of cervical fracture of some teeth for which reason the patient went to local doctors for several time and extractions were done. With these problems the patients was very anxious and came for correct diagnosis of the condition.

Local causes are thought to be the most frequent for external root resorption, caused by excessive pressure and inflammation. Mechanisms include large orthodontic forces, occlusal trauma, impacted teeth, re-implanted teeth, periradicular infection or tooth bleaching.<sup>16</sup> In an attempt to explain the cause of idiopathic external root resorption, Pinska and Jarzynka<sup>17</sup> first suggested genetic susceptibility in their report of a family with generalized root resorption. Our patient had no such history that can be considered for diagnosis.

Many systemic abnormalities have been implicated for external root resorption, which include hormonal disturbances,<sup>18</sup> hypophosphatasia,<sup>19</sup> hyperparathyroidism,<sup>20</sup> Paget's disease,<sup>21</sup> Regional odonto dysplasia (Ghost Disease) and bone dysplasia<sup>22</sup>. Hypothyroidism<sup>25</sup> may have a similar radiographic presentation to external root resorption. During the entire period of attending the patient, thyroid and parathyroid hormone assay were done but were within normal limits. In hypophosphatasia, total urine phosphate level is usually reduced but in the case it was normal. The cases presented in this article did not have obvious local or systemic causative factors for their root resorption patterns.

Histo-pathological findings of curreted gingival tissues in external resorption showed presence of osteoclasts in association with inflammatory cells<sup>24</sup>. But in this case, histological report revealed presence of hyperkeratosis, parakeratosis, mild acanthosis and mild dysplastic changes in lining epithelium. There was mild infiltration of chronic inflammatory cells in subepithelial region. The findings also differ from ghost tooth as in that condition gingival biopsy show odontogenic tissue in the epithelium and intra mesenchymal calcification<sup>25</sup>. So, the histopathology also cannot confirm of any diagnosis.

In the present case, teeth also exhibited external root resorption in the cervical area, and all the resorbed teeth were shown to be vital by the pulp test. There were no symptoms such as hypersensitivity or pulpitis. Radiographic findings showed cervical external root resorption with a scalloped margin that undermined enamel and extended for a variable distance down the root surface toward the dental pulp. During treatment via mucosal flaps, root resorption was restricted to the proximal site, and was not observed at buccal or lingual sites. Liang et al<sup>2</sup> reported that in all patients, the condition began at the mesial or distal cemento-enamel junction, and usually progressed to involve the entire cervical region.

Progressive resorption of teeth has previously been reported in cases of Paget's disease.<sup>26-28</sup>

In the present case, Paget's disease was suspected, but serum alkaline phosphatase was not elevated, and radiographs did not show the typical cotton-wool or ground glass appearance from head to foot. In the maxillary and mandibular region, there was no sign of Paget's disease like hypercementosis, loss of lamina dura or cotton wool appearance of the osseous tissues. Kerr et al<sup>29</sup> reported a case of multiple idiopathic root resorption with elevated serum alkaline phosphatase. But the patient presented cervical external root resorption in different teeth without elevated alkaline phosphatase.

Regional odontodysplasia/Ghost tooth) also been suspected but rest of the permanent teeth that the patient had at that time were of normal anatomy where the ghost teeth are clinically likely to be small, brown, grooved and hypoplastic. There was no history of eruption failure or delay. There were no history of abscesses or fistulae in the affected teeth which is common in regional odontodysplasia.<sup>11-16</sup> On radiographs, the enamel and dentine lack contrast, rendering the tooth ghost like appearance<sup>1,2</sup> but in the present case the enamel and dentine can be clearly distinguished. Moreover, Regional odontodysplasia is usually unilateral<sup>6-8</sup> but our case crossed the midline and affected teeth of both jaw sequentially.

Treatment of inflammatory root resorption due to pulpal infection consists of long-term calcium hydroxide therapy<sup>32,33</sup>. Other treatment plans such as application of low

power laser<sup>34</sup> or even single visit root canal therapy with gutta percha<sup>35</sup> have also been suggested. The conventional treatment plan in invasive cervical root resorption is to remove the granulation tissue and restore the resorption defect<sup>32</sup>. The main goal in these treatment plans is to remove the etiological factors and stop the resorption process. However, in idiopathic resorption the cause is unknown and therefore, the treatment is still the challenge.

In present case the resorption of teeth were followed up for 6 years being unable to extract any clue for proper diagnosis and progressive resorption cannot be arrested in spite of all treatment strategy adopted which indicates that the pathology was idiopathic.

#### References:

1. George DI, Miller RL. Idiopathic resorption of teeth: a report of three cases. *Am J Orthod* 1986;89:13-20.
2. Liang H, Burkes EJ, Frederiksen NL. Multiple idiopathic cervical root resorption: systematic review and report of four cases. *Dentomaxillofac Radiol* 2003;32:150-5.
3. Mueller E, Rony HR. Laboratory studies of an unusual case of resorption. *J Am Dent Assoc* 1930;XVII:326-34.
4. Kim PH, Heffez HB. Multiple idiopathic resorption in the primary dentition. Review of the literature and case report. *Oral Surg Oral Med Oral Pathol Oral Radiol Endod* 1999;88:501-5.
5. Carr HG. Multiple idiopathic resorption of teeth. *Br Dent J* 1958; 105:455-6.
6. Kerr DA, Courtney RM, Burkes EJ. Multiple idiopathic root resorption. *Oral Surg Oral Med Oral Pathol* 1970;29:552-65.
7. Hopkins R, Adams D. Multiple idiopathic resorption of the teeth. *Br Dent J* 1979;146:309-12.
8. Lydiatt DD, Hollins RR, Peterson G. Multiple idiopathic root resorption: diagnostic considerations. *Oral Surg Oral Med Oral Pathol* 1989;67:208-10.
9. Moody AB, Speculand B, Smith AJ, Basu MK. Multiple idiopathic external resorption of teeth. *Int J Oral Maxillofac Surg* 1990;19:200-2.
10. Gunraj MN. Dental root resorption. *Oral Surg Oral Med Oral Pathol Oral Radiol Endod* 1999; 88: 647-653.

11. Bakland LK. Root resorption. *Dent Clin North Am* 1992; 36: 491–507.
12. George DI, Miller RL. Idiopathic resorption of teeth. *Am J Orthod* 1986; 89: 13–20.
13. Newman WG. Possible etiologic factors in external root resorption. *Am J Orthod* 1975; 67: 522–539.
14. Brady J, Lewis DH. Internal resorption complicating orthodontic tooth movement. *Br J Orthod* 1984;11:155-7.
15. Estrela C, Bueno MR, De Alencar AHG, Matter R, Valladares Neto J, Azevedo BC, De Araujo Estrela CR. Method to evaluate inflammatory root resorption by using cone beam computed tomography. *J Endod.*2009;35(11):1491-7.
16. Ruđiger S, Berglundh T. Root resorption and signs of repair in Papillon-Lefevre syndrome: a case study. *Acta Odontol Scand* 1999; 57: 221–224.
17. Pinska E, Jarzynka W. Spontaneous resorption of the roots of all permanent teeth as a familial disease. *Czas Stomatol* 1966; 19: 161–165.
18. Hopkins R, Adams D. Multiple idiopathic root resorption of the teeth. *Br Dent J* 1979;146:309-12.
19. Pankhurst CL, Eley BM, Moniz C. Multiple idiopathic external root resorption: a case report. *Oral Surg Oral Med Oral Pathol* 1988; 65: 754–756.
20. Pietokovski J, Menchel J. Tooth dwarfism and root underdevelopment following irradiation. *Oral Surg Oral Med Oral Pathol* 1966; 22: 95–99.
21. Logan J. Dentinal dysplasia. *Oral Surg Oral Med Oral Pathol* 1962; 15: 317–333.
22. Sunde OE. Dental changes in a patient with hypoparathyroidism. *Br Dent J* 1961; 111: 112–117.
23. Muller E, Rony HR. Laboratory studies of an unusual case of resorption. *J Am Dent Assoc* 1930;17:326-34.
24. Ingle JJ. *Ingle's Endodontics*. 6<sup>th</sup> edition. Pmph USA Limited;2008.pp.1358-80.
25. Mostofa MI, Taha NS, Mehrez MAI. Generalized versus Regional Odontodysplasia: Diagnosis, Transitional Management, and Long-Term Followup- A Report of 2 Cases. *Case reports in Dentistry* 2013;2013:1-5.
26. Gergely JM. Monostotic Paget's disease of the mandible. *Oral Surg Oral Med Oral Pathol* 1990;70:805-6.
27. Barnett F, Elfenbein L. Paget's disease of the mandible—a review and report of a case. *Endod Dent Traumatol* 1985;1:
28. Smith NH. Monostotic Paget's disease of the mandible presenting with progressive resorption of the teeth. *Oral Surg Oral Med Oral Pathol* 1978;46:246-53.
29. Kerr DA, Courtney RM, Burkes EJ. Multiple idiopathic root resorption. *Oral Surg Oral Med Oral Pathol* 1970;29:552-65.
30. Trope M, Moshonov J, Nissan R, Buxt P, Yesilsoy C, Short Vs Long-termcalcium hydroxide treatment of established inflannatory root resorption in replanted dog teerh endod dent traumato-1996; 11 (3) : 124-8
31. Vatanpour M, Javidi M, Zarei , Shirazin S. External root resorption: attested or progressing? *Iran endod J.* 2009; 3(3): 93-4
32. Asgary S, Ahmadyer, M. One visit RCT of Maxillary incisors with extensive inflammatomy roof resorption and peri radicular lesions: A case Report. *Iraz endod J roll;* 6 (2): 95-8