

Original Article

Radiographic position of mental foramen in selected urban population of Bangladesh.

* Tazdik G. Chowdhury^a, Dilruba Rahman^b, Tasnim-A-Jannat^c, Md. Mahfuz Hossain^d, Asma Sultana^e, Md. Ashif Iqbal^f, Ashek Elahi Noor^g

a. Assistant Professor and Head, Dept. of Paediatric Dentistry, Update Dental College and Hospital

b. Lecturer, Dept. of Dental Public Health, Update Dental College and Hospital

c. MPH(On course), Department of Health promotion & Health Education, Bangladesh University of Health Science.

d. Associate Professor & Head Department Of Oral Anatomy, Update Dental College & Hospital

e. Assistant Professor & Head, Department of Science of Dental Material, Update Dental College & Hospital

f. Assistant Professor, Department of Oral Pathology & Periodontology, Update Dental College & Hospital, Dhaka

g. Lecturer, Dept. of Dental Public Health, Sapporo Dental College and Hospital

ARTICLE INFO

Article history:

Received : 10.12.15

Accepted :09.02.15

Key words:

Mental foramen (MF), Mandible, Horizontal Position, Orthopantomogram (OPG).

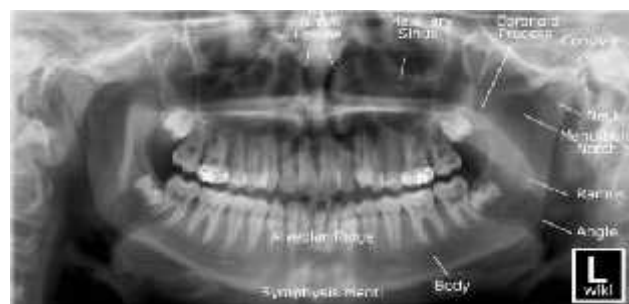
ABSTRACT

Purpose of this study was to investigate the most common accurate position of the mental foramen in selected Bangladeshi population which helps in several clinical procedure and nerve block anesthesia. The study sample included one hundred and one panoramic radiographs of selected urban population of Bangladesh taken in Out Patient Department, Update Dental College, Dhaka, Bangladesh. The most common Horizontal position of the mental foramen was below the root of second premolar tooth (37.6%). In vertical axis, the location of MF in lower half of body of mandible was found in all OPGs (100%). In vertical distance, Position B, which is measured by distance between 1.0 mm to 1.5 mm, is the most common position of MF in all aspect as viewed in OPGs in Bangladeshi population. In this study, the difference of the location of the mental foramen in different ethnics groups was discussed. Clinicians and anthropologists should expect to find the position of the mental foramen to be symmetrical and below the root of second premolar tooth.

Introduction

Mental foramen is an important anatomical landmark. It is located on the anterolateral aspect of the body of mandible, lateral to and above the mental tubercle. It is felt as a slight depression. It gives passage to the mental nerve and vessels.^{1,2,3} Mental foramen is located about 2.8-4 cm from the median fusion of the two halves of the mandible (Symphysis menti) and lies in lower half of the mandible in vertical axis. Mean diameter of mental foramen is reported to be 3.8 mm.^{4, 5,6} Anatomically there is one mental foramen each on each side of mandible. Variation in number of mental

foramina also been reported. More than one mental foramina in one side ranges from 2% to 10%^{9, 10}, whereas up to 0.06% incidence of absence of mental foramina is also reported.¹³



ORTHOPANTOGRAM (OPG) gives a panoramic view of the mandible and teeth. On an OPG, mental foramen is visible as a round or oval radiolucency. Generally it is situated in the lower half of the body of mandible in

* Address of Correspondence

Dr. Tazdik G. Chowdhury,

BDS, DDS

Assistant Professor and Head

Dept. of Paediatric Dentistry,

Update Dental College and Hospital,

Dhaka, Bangladesh.

Mobile: 01711-047904

E-mail: tazdik4152012@gmail.com

vertical axis, 1-2 mm below the apices of the adjacent teeth. The aim of this study is identification of the accurate anatomical location of the MF helps in several clinical procedure and nerve block anesthesia. Identification of the accurate

Methodology

This study was based on one hundred and one (OPGs) of adult patients. This was a non-probability convenient sampling, cross sectional study design. The study was conducted during a period of six months from 15th September 2011 to 14th March 2012 at Out Patient Department, Update Dental College, Dhaka, Bangladesh. All OPG were examined two times in a dark room on an X-ray viewer. Here the mental foramen was located as radiolucency, traced by following the inferior alveolar canal. The data was analyzed by (SPSS Version 16), Following some inclusion & Exclusion Criteria was used.^{15,19,23}

Inclusion criteria are (1) Age 15 and above (2) Film should show no radiographic exposure and processing artifacts. (3) OPG of adult patient of both sexes with permanent dentition at least having first molar teeth bilaterally. (4) Radiographs having bilaterally visible mental foramina taking by same machine.

Exclusion Criteria are (1) Radiograph of edentulous patients (2) Radiograph showing incomplete or mixed dentition (3) Radiograph with pathologic lesion (4) Unreadable and poor quality of OPG (5) Missing teeth, especially missing lower canine must be excluded when mesial premolar drift occur (6) Presence of supernumerary teeth in mandibular dentition (7) Presence of periodontal lesion in mandibular dentition that may cause dental mesial drift (8) Patients with previous and current orthodontic treatment.

Radiographic measurement:

The accurate position of mental foramen is observed by many researchers using data from different ethnic and racial groups. There both horizontal and vertical positions are described.

The horizontal position in relation to the apices of adjacent teeth is more emphasized in

anatomical location of MF helps in endodontics surgery, periapical surgery, surgical orthodontics exodontia, perprosthetic surgery, implant surgery, management of trauma and fracture in mandibular body and nerve block anesthesia.¹

different clinical procedures. Commonest position of mental foramen is described to be apical to the second premolar tooth^{13,14,15,17} and between the roots of two mandibular premolar teeth.^{18,19} Most of the researchers classify the position of mental foramen in following position.¹⁴⁻¹⁹

position 1: MF situated anterior to the first premolar tooth. **position 2:** MF situated in the line with the long axis of first premolar tooth. **position 3:** MF Situated between the apex apices of the first and second premolar teeth. **position 4:** MF situated in the line with the long axis of second premolar tooth. **position 5:** MF Situated between the apex apices of the second premolar and first molar teeth. **position 6:** MF situated in the line with the long of first molar tooth.

The vertical position mental foramen was viewed by two angles. One was vertical axis and another was Vertical distance.

In vertical axis **position 1:** The location of MF in lower half of body of mandible. **position 2:** The location of MF in upper half of body of mandible¹⁴⁻¹⁸.

In vertical distance, the distance between the mental foramen to the lower border of mandible was measured on both side of OPGs. Here distance was measured from lower border of mental foramen to the lower border of mandible and upper border of mental foramen to the lower border of mandible on both sides of OPGs.²⁴ **Position A :** Distance between 0.4 mm to 0.9 mm. **Position B :** Distance between 1.0 mm to 1.5 mm. **Position C :** Distance between 1.6 mm to above.

Results

Table 1: Age & Gender Distribution

Age in years	Frequency	%
11-20 yrs	10	9.9
21-30 yrs	34	33.7
31-40 yrs	31	30.7
41-50 yrs	13	12.9
51-60 yrs	9	8.9
61-70 yrs	4	4.0
Gender		
Male	69	68.3
Female	32	31.7

Total	101	100.0
--------------	------------	--------------

The age of the subjects ranged from 15 years to 70 years (mean age 28.33). Highest age group from 21 to 30 years (33.7%), and lowest was 61 to 70 years (4.0%). Gender distribution shows male predominance with males being 68.3% (n=69) and females being 31.7% (n=32) as shown in Table 1

Table 2. Location of Mental Foramen (in Horizontal axis)

Horizontal position	Right side		Left side	
	Frequency	Percent	Frequency	Percent
Position 1	7	6.9	4	4.0
Position 2	9	8.9	10	9.9
Position 3	34	33.7	37	36.6
Position 4	38	37.6	38	37.6
Position 5	9	8.9	10	9.9
Position 6	4	4.0	2	2.0
Total	101	100.0	101	100.0

Position 1 was found to be in 7 OPGs on the right side and 4 OPGs on the left side. Its frequency was reported as 6.9 % on the right side and 4.0% on the left side. **Position 2**, was found to be in 9 OPGs and frequency was reported as 8.9% on the right side and in 10 OPGs on the left side where frequency was 9.9 % . **Position 3** was found to be in 34 OPGs & frequency is 33.7% on the right side and 37 OPGs on left side and frequency is 36.6 % . **Position 4** was found to be in 38 OPGs on both sides. Its frequency was 37.6%. Hence, Position 4 is the most common position of MF as viewed in OPG. **Position 5**, was found to be in 9 OPGs on the right side and 10 OPGs on the left side. Its frequency was 8.9% on the right side and 9.9

% on the left side. **Position 5** and **Position 2** is the third most common location of MF as viewed in OPGs. **Position 6** was found to be in only 4 OPGs and 2 OPGs on the right and left side. Its frequency was reported as 4.0 % and 2.0% for the right and left side. Position 6 is the least common position of MF as viewed in OPG as shown in Table 2.

Table 3. In Vertical axis Location of Mental Foramen

Position	Frequency	%
Position 1	100	100
Position 2	0	0

In vertical axis Position 1, was found in all OPGs. Its frequency was 100%. While Position 2, was totally absent with 0 % as shown in Table 3.^{19,23}

Table 4: Vertical distance from lower border of mental foreman to the lower border of mandible

Position	Right side		Left side	
	Frequency	Percent	Frequency	Percent
Position A	26	25.7	24	23.8
Position B	58	57.4	67	66.3
Position C	17	16.8	10	9.9
Total	101	100.0	101	100.0

Table 5: Vertical distance from upper border of mental foreman to the lower border of mandible

Position	Right side		Left side	
	Frequency	Percent	Frequency	Percent
Position A	7	6.9	5	5.0
Position B	53	52.5	61	60.4
Position C	41	40.6	35	34.7
Total	101	100.0	101	100.0

In Vertical distance, **Position A** was found to be in 26 OPGs on the right side and 24 OPGs on the left side from lower border of mental foreman to the lower border of mandible. Its frequency was 25.7% on the right side and 23.8% on the left side and 7 OPGs on the right side and 5 OPGs on the left side from upper border of mental foreman to the lower border of mandible. Its frequency was 6.9% on the right side and 5.0 % on the left side. **Position B** was found to be in 58 OPGs on the right side from lower border of mental foreman to the lower border of mandible and 67 OPGs on the left side from lower border of mental foreman to the lower border of mandible. Its frequency was 57.4% on the right side and 66.3% on the left side and 53 OPGs on the right side from upper border of mental foreman to the lower border of mandible and 61 OPGs on the left side from upper border of mental foreman to the lower border of mandible. Its frequency was 52.5% on the right side and 60.4% on the left side. **Position C** was found to be in 17 OPGs on the right side and 10 OPGs on the left side from lower border of mental foreman to the lower border of mandible. Its frequency was 16.8% on the right side and 9.9% on the left side and 41 OPGs on the right side and 35 OPGs on the left side from upper border of Mental foreman to the lower border of mandible. Its frequency was 40.6% on the right side and 34.7% on the left side. Hence; Position B is the most common position of MF

in all aspect as viewed in OPGs shown in Table 4 & Table 5.

Discussion

Determination of position of mental foramen has been a topic of great interest for the investigators emphasizing on important anatomical land marks of the maxillofacial region.¹⁹ Radiography is the only available non-invasive method for diagnosis and treatment planning of major surgical procedures of the mandible.^{25,26}

We utilized panoramic radiographs because they have certain advantages over intra-oral radiography. It includes a greater area of hard and soft tissues and also the visualized area in continuity, thus allowing for a more accurate location of the mental foramen in both the horizontal and vertical dimensions. On the other hand, periapical radiographs may not show several positions of the mental foramen if it is below the edge of the film²⁸

In the research literature the mental foramen is frequently described as situated in the region of the second premolar in the fully developed mandible.^{28,29,30} Sample size of the studies above varied between 40 to 2000.³¹ In our study our sample size was 101 people. The weighted frequency of the location of the mental foramen in the above studies was in position 3. But in our study most common

position in horizontal axis is position 4. Position 3 is the second most common position. Our study design and results were similar with Gungor 's and Jasser's study design^{26,34} shown (Table 6).

In vertical axis, position 1 was found in all OPGs (100%) is similar to another Pakistani study¹⁹.

In vertical distance, Position B is the most common position of MF in all aspect as viewed in OPGs.

Although our study is limited with a group of people; according to the analyze of the Table 10, our results are almost similar with the other countries. But also advanced studies are necessary to achieve clearer results.

Table 6, Summary data on the Horizontal position of the mental foreman (K. Gungor et al.: Location of Mental Foramen in Turkish Population, Coll. Antropol. 30 (2006) 4: 801–805) and (Jasser and Nwou1998, Gungor et al)

Reference	Population	Sample size	Distribution %											
			1		2		3		4		5		6	
Jasser and Nwoku	Saudis	794	0.6		5.3		42.7		45.3		5.2		0.9	
K Gungor et al	Turkish	722	1.2		3.2		71.5		22.4		1.7		0.0	
Present study	Bangladesh	101	Right side 6.9	Left side 4.0	Right side 8.9	Left side 9.9	Right side 33.7	Left side 36.6	Right side 37.6	Left side 37.6	Right side 8.9	Left side 9.9	Right side 4.0	Left side 2.0

Conclusion

In conclusion, according to our results the location of the mental foramen on the panoramic radiographs of selected Bangladeshi population was most commonly in the line with the long axis of second premolar tooth. In majority of cases there was bilateral symmetry in the position. Location of mental foramen is studied in cadavers, intraoperatively and radiographically. Ethical issues, limitation of sample size and procedural difficulties have limited the cadaveric and intraoperative studies a lot. Whereas, radiographic studies have made a large account of studies of position of mental foramen, as these are easily accessible, large sample sizes available and non-invasive.^{25,26} Clinicians and anthropologist should expect to find the positions of the mental foramen to be symmetrical and in the line with the long axis of second premolar tooth.

References

1. Fishel D, Boucher A, Hershkowitz A, Kaffe I. Roentgenologic study of the mental foramen. *Oral Surg Oral Med Oral Pathol* 1976; 41:682-86.
2. Jennifer Neo, The Position of the Mental Foramen In Singaporean Malays and Indians. *Anesth Prog* 36:276-278 1989

3. tadioLaaphic assessment of mental foramen appearance in panoramic radiographs. *Pakistan Oral & Dent Jr.* 2005; 25: 225-28.
4. Igbigbi P.S. and Lebona S. The position and dimensions of the mental foramen in adult **Malawian mandibles**. *West Afr J Mcd.* 2005;24: 184-89
5. Smagilagic A. Dilbcrovic F. Clinical and anatomy study of human mental foramen. *Bosn J Basic Mcd Sci.* 2004; 4: 15-23.
6. Souaga K. Adou A. Angoh Y. Topographical and morphological study of the mandibular foramen in black Africans from the Ivory Coast. *Odontostomatol Trop.* 2004; 27: 17-21
7. Arzouman MJ. Otis L. Kipnis V. Levine D. Observation of Maxillofacial Implant. 1993;8: 295-300. Kicscr J. Kuzmanovic D. Payne A. Dennison J. Hrbison P. Patterns of emergence of the human mental nerve. *Arch Oral Biol.* 2002; 47:743-47
8. Mwaniki DL. Ilasanali J. The position of mandibular and mental foramina in Kenyan African mandibles. *East Afr Mcd J.* 1992; 69:210-13.
9. Igarashi C. Kaoru K. Akira Yamamoto, Yasuhiko Morita and computed

- tomoL^rrapl)\ images: Oral Radiolo<£\ Volume 20. Number 2 Dale: December 2004 Pages: 68 71 Available :hup; www.sptinLrerlink.com content.\m5yrmm31pmkjqm
10. Zografos J. MulzuriA. Incidence of double mental foramen in a sample of Greek population. *OdontostomatolProodos*. 1989;43:521-23.
 11. de Freitas V. Madeira MC. Toledo Filho JL. Chagas CF. Absence of the mental foramen in dry human mandible;. *ActaAnat (Basel)*. 1979; 104:353-55.
 12. Gcrshcnson A. Nathan II. Luchansky E. Mental foramen and mental nerve: changes with age. *ActaAnat (Basel)*. 1986;126:21-28.
 13. Shankland WE 2nd. The position of the mental foramen in Asian Indians. *JOrallImplantol*. 1994;20:118-23.
 14. Ngcow WC. YuzawatiY. The location of thcmental foramen in a selected Malay population. *J Oral Sci*. 2003; 45:171 -75.
 15. Julian R D. Position of the mental foramen in a North American, white population. *Oral Surg Oral Mcd Oral PatholOralRadiolEndod*. 1998;85:457-60
 16. Mbajiorgu EF, Mawera G, Asala SA, Zivanovie S. Position of the mental foramen in adult black Zimbabwean mandibles: a clinical anatomical study. *Cent Afr J Mcd*. 1998; 44: 24-30
 17. AUasscrNM.Nwoku AL. Radiographic study of thcmental foramen in a selected Saudi population. *DentomaxillofacRadiol*. 1998; 27:341-43.
 18. Wang TM. Shih C. Liu JC. Kuo KJ. Aclinical and anatomical study of the location of the mental foramen in adult Chinese mandibles. *ActaAnat (Basel)*.1986; 126:29-33
 19. Punjabi S K, Rehman H U,AhmedS,Haider M, Radiographic Position of mental foremanin selected pakistanipopulation. *Journal of the Pakistan Dental Association*,Vol.19,2 Apr-Jun2010
 20. Rouas P., D'incau E., Jordana F, and Rouas A. Validity of aCraniofacialBiology. 2003; 25: 61-3.
 21. Al Reader & John N. Local anesthesia for endodontic pain *Endodontic Topics*. 2002; 3: 14.
 22. Jaffar AA. Al-Zubaidee AF. and Al-Salihi AR. Anatomical Features of Clinical Significance In Dry Mandibles [Online] [Cited on July 2006]. Available from: URL:http:."wvww.geoeilies.comakram jlr features ol' mandibles.
 23. <http://www.wsrjournals.org/download.php?pid=976087441542779314.pdf&type=applicationpdf&file=Location+of+mental+foramen+among+Malaysia+populations%3A+Retrospective+study+by+using+orthopantomogram.pdf>
 24. <http://www.wsrjournals.org/download.php?pid=976087441542779314.pdf&type=applicationpdf&file=Location+of+mental+foramen+among+Malaysia+populations%3A+Retrospective+study+by+using+orthopantomogram.pdf>
 25. Kaffe,I.,L.Ardekian,I.Gelerenter,S. Taicher,Location of the mandibular foramen in panoramic radiographs *Oral Surg. Oral Med. Oral Pathol.*, 78 (1994) 662.
 26. K. Gungor et al.: Location of Mental Foramen in Turkish Population, *Coll. Antropol*. 30 (2006) 4: 801–805
 27. Kjaer, I., Scan. J. Formation and early prenatal location of the human mental foramen *Dent. Res.*, 97 (1989) 1.
 28. Phillips,J.L.,R.N.Weller,J.C.Kulild, The mental foramen: 2. Radiographic position in relation to the mandibular second premolar *J. Endod.*, 18 (1992) 271.
 29. Phillips JL, Weller RN, Kulild JC. The mental foramen: 3. Size and position on panoramic radiographs. *J Endod*. 1992 Aug;18(8):383-6.
 30. Phillips JL, Weller RN, Kulild JC. The mental foramen: 1. Size, orientation, and positional relationship to the mandibular second premolar. *J Endod*. 1990 May;16(5):221-3.
 31. Sicher,H.,E.Du Brul: *Oral anatomy*. (The CV Mosby Co., St. Louis,

- 1975). Third molar root encircling dental nerve and vessels. in: ed 6. C. V. Mosby Co, St. Louis; 1975:428–429. 29 . ps.
32. Green,R.M. The position of the mental foramen: a comparison between the southern (Hong Kong) Chinese and other ethnic and racial groups Oral Surg Oral Med Oral Pathol. 1987 Mar;63(3):2q23q2387-90.
 33. Shankland,W.E., The position of the mental foramen in Asian Indians.J. Oral Implantol., 20 (1994) 118.
 34. Jasser,N.M.,A.L.Nwoku,Radiographic study of the mental foramen in a selected Saudi population.Dentomaxillofac. Radiol., 27 (1998) 341.