



Comparison between infiltration and inferior alveolar nerve block anesthesia for extraction of Advance periodontitis of mandibular molars

*Haque M M¹, Anisuzzaman M M², Hasan S³, Adnan N⁴

AFFILIATION:

- Muhammad Mubashirul Haque; MS, BDS**
Assistant professor,
Department of Periodontology and Oral Pathology
BIRDEM General Hospital, Shahbag, Dhaka, Bangladesh
- Dr. Mostafa Md. Anisuzzaman; FCPS, BDS**
Lecturer, Department of oral and Maxillofacial Surgery
Ibrahim Medical College (Dental Unit), Shahbag, Dhaka, Bangladesh
- Dr. Sajid Hasan; FCPS, BDS**
Assistant professor, Department of oral and Maxillofacial Surgery
Ibrahim Medical College (Dental Unit), Shahbag, Dhaka, Bangladesh
- Dr. Nubad Adnan; BDS**
Medical officer, Dental Surgery Department
Birdem General Hospital, Shabagh, Dhaka, Bangladesh

Article info.

Received: 10 November 2019

Accepted: 11 January 2020

Volume: 10, Issue-1 April, 2020

DOI: <https://doi.org/10.3329/updcj.v10i1.46686>



© Authors retain copyright and grant the journal right of first publication with the work simultaneously licensed under Creative Commons Attribution License CC - BY 4.0 that allows others to share the work with an acknowledgment of the work's authorship and initial publication in this journal.

<https://creativecommons.org/licenses/by/4.0/>

Publisher: Update Dental College, Dhaka, Bangladesh

Web: www.updatedentalcollege.edu.bd

E-mail: updcj@hotmail.com

* Corresponding Author

Muhammad Mubashirul Haque; MS, BDS

Assistant professor,

Department of Periodontology and Oral Pathology

BIRDEM General Hospital (Dental Unit)

Shahbag, Dhaka, Bangladesh

E-mail: mubashirulms7777@gmail.com



Citation

Haque M M, Anisuzzaman M M, Hasan S, Adnan N. Comparison between infiltration and inferior alveolar nerve block anesthesia for extraction of Advance periodontitis of mandibular molars. UpDCJ. 2020 Apr;10(1):13-15. Available from: DOI: <https://doi.org/10.3329/updcj.v10i1.46686>

ABSTRACT

Aim: The focus of the education was to assess the success between local-anesthetic infiltration injection and inferior alveolar nerve block anesthesia in extraction of Chronic periodontitis mandibular posterior teeth.

Methods: 100 patients aged between 13 and 73 years who attended the Department of Dental surgery, BIRDEM General Hospital for extraction of advance periodontitis of mandibular molars were included in this study. For the infiltration anesthetic technique, patient's approval was taken. The patients were equally divided into two groups. Group (1) received 0.6 ml out of 1.8 ml of 2% lidocaine with 1:80000 adrenaline injection buccally and the same amount infiltration lingually opposite the intended tooth. Group (2) received 1.5 ml out of 1.8 ml of 2% lidocaine with 1:80000 and the remaining 0.3 ml was injected for long buccal nerve anesthesia.

Results: In this Study we found 88% patients were pain free and Group-2 94% patients were pain free During extraction of Advance periodontitis of mandibular molars. P-value was 0.138 and it was not < 0.05. So it was not significant. On the other side 103 patients out of 113 were pain free in male and 79 patients out of 87 were pain free in female and 6 patients out of 87 were feeling pain during tooth extraction of advance periodontitis of mandibular molars. P-value was 0.138 and it was not < 0.05. So it was not significant.

Conclusion: Infiltration anesthesia for non-vital mandibular molars is effective as a substitute for inferior alveolar block technique.

KEYWORDS: Infiltration technique, inferior alveolar nerve block, non-vital teeth, lidocaine.

INTRODUCTION

Local anesthesia is the most frequently used treatment procedure for pain control through medical and dental procedures.¹ However, the Local anesthesia injection oneself has been expressed as the only recognize painful factor of dental procedure, and the combined fear of this injection is usually designed a factor in avoiding dental treatment.² Various studies have measured factors certain fear, as well as success and capability of Local anesthesia injections, including tissue dispensability, speed of injection,³ solution temperature,⁴ and patient characteristics.⁵ In addition, the type of procedure has been expressed to have an important role in positive pain anticipated at the time of injection or extraction.⁶

The inferior alveolar nerve block is the most regularly used injection accession for complete local anesthesia for mandibular restorative and surgical procedures of the posterior region. Successful inferior alveolar nerve block associates a degree of difficulties that compose the injection stressful for both the clinician and the patient.⁷

Major postoperative complications may take place with the use of block anesthesia of the inferior alveolar nerve which comprise lengthened mandibular anesthesia, during this time the patient may injure his or her tongue or lip in a range of ways, systemic toxicity from iatrogenic intra- arterial injection of local anesthetic solution, injury to the inferior alveolar nerve,⁸ difficulty in carry out anesthesia because of anatomic

variations, deep and invasive needle penetration; paresthesia; muscle trismus; hematoma formation; high prevalence of positive aspiration; and difficulty in hemostasis in patients with bleeding disorders.⁹ Infiltration anesthesia has been escaped in the mandibular molar regions because of dens bone that does not grant adequate diffusion of the anesthetic solution to the bone.⁷ This study attract on the effectiveness of mandibular infiltration correlated with inferior alveolar nerve block in the extraction of Chronic periodontitis mandibular posterior teeth.

METHODS:

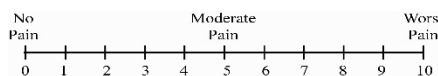
This study is prospective cohort clinical study. The study included 200 patients who attended the Department of Dental Surgery, BIRDEM General Hospital, Shahbag, Dhaka, Bangladesh. Consent was obtained from each patient participated in this study. The patients were equally divided into two groups. Group 1: Infiltration technique was used to anaesthetize mandibular posterior Chronic periodontitis teeth using 0.6 ml out of 1.8 ml of 2% lidocaine from one dental cartridge with 1:80000 adrenaline injections.

Two injections 0.6 ml for each tooth were given against and parallel to the long axes of the offended tooth. One injection was in the buccal vestibule targeting the long buccal nerve by which soft and hard tissues were anaesthetized, using short needle and dental syringe. The second injection was in the lingual vestibule of the floor of the mouth by which lingual soft and hard tissue was anaesthetized, using short needle and dental syringe. Group 2: two injections were given 1.5 ml of 2% lidocaine used for inferior alveolar nerve block, and the second one was performed with the remaining 0.3 ml for long buccal nerve infiltration.

Teeth included in this study were non infected mandibular premolars, first and second molars. Local anesthesia and dental extraction was performed for all cases by the same surgeon. The success of anesthesia was checked within 3-5 minute subjectively (verbal) by asking the patient about the presence of numbness in the anaesthetized region. Objective test was also done by applying a probe at depth of the gingival margin from mesial to distal buccally and lingually, while the reaction and response of the patient was noted. Visual analogue pain scale used during dental extraction to assess the pain. This scale labeled no pain, mild, moderate and severs pain.¹⁰ If there was no pain the extraction was completed using dental forceps or elevators, and then instructions were given to the patient. If pain was observed whether mild, moderate or severe in group 1 the procedure was ceased and inferior alveolar nerve blocked was given to the patient.

STATISTICAL ANALYSIS:

Chi-square test was used for analysis of the data with significance level at $P \leq 0.05$.



RESULTS:

A total of 200 patients (87 females and 113 male) with a mean age of 39.2 year were enrolled in this study.

Table 1: Pain during dental extraction in relation to the anesthetic technique (n=200).

| GROUP | Pain | Percentage % | No Pain | Percentage% | p-value |
|---------|------|--------------|---------|-------------|---------------------|
| Group-1 | 12 | 12% | 88 | 88% | 0.138 ^{ns} |
| Group-2 | 6 | 6% | 94 | 94 % | |

Chi-square test, ns = not significant

Table 1 Showing Pain during extraction in 12% cases and no pain in 88% cases in group 1 patient. In group 2 pain during tooth extraction in 6% cases and no pain in 94%cases. P-value was 0.138 and it was not < 0.05. So it was not significant.

Table 2: Pain during dental extraction in relation to the gender (n=200).

| GROUP | Pain | Percentage % | No Pain | Percentage% | Total |
|--------|------|--------------|---------|-------------|---------------------|
| Male | 10 | 8.85% | 103 | 91.1% | 0.932 ^{ns} |
| Female | 8 | 9.2% | 79 | 90.8% | |

Chi-square test, ns= significant

Table 2 Showing Pain during extraction in 8.85% cases and no pain in 91.1% cases in male patient. In female pain during tooth extraction in 9.2% cases and no pain in 90.8% cases. During extraction of Advance periodontitis of mandibular molars. P-value was 0.138 and it was not < 0.05. So it was not significant.

DISCUSSION:

Hence, considering all the complications and side effects of inferior alveolar nerve block, suprapariosteal infiltration procedure is effortless to practice, complication rate is minor than inferior alveolar nerve block, and its anesthetic outcome is shorter and it is much more presentable in terms of patient's pain sufferance and postoperative convenience. Mandibular bone is treated as too dense and too compact and because of this dense structure, it is reflection that local anesthetic cannot be diffused into the medullary space of mandible by suprapariosteal infiltration. 15 patients out of 44 were absolutely pain free by using infiltration for extracting non vital posterior teeth¹¹.

In this Study we found 88% patients was pain free and 12% was filing pain during tooth extraction in Group-1. Again in Group-2 94% patients was pain free and 6% was filling pain During tooth extraction. These data fortitudes the knowledge of endurance of accessory foramina in the mandible, it has been form that 2449 accessory or unnamed foramina in 300 dried human mandibles.¹² Madeira et al.¹³ reported the presence of accessory foramina in the human mandible in 87.3 to 96.2% of specimens studied. Pogrel et al reported that division of the mental nerve reenter the labial (lateral) surface of the mandible to supply lower incisors. Based on the beyond considered agreement and our results, the deed of suprapariosteal infiltration anesthesia at the posterior region of the mandible might be akin with the possibility of diffusion of local anesthetic solution within the bony structures.¹⁴

Because the non-vital teeth absence pulpal tissue and since the inferior alveolar nerve supply the dental pulp, so allowing anesthesia to the inferior alveolar nerve is no longer necessary

and to avoid its complications its more constructive and scientific to use infiltration technique to anaesthetized the long buccal nerve and lingual nerve. A sensitivity that infiltration techniques may not be the first preference in the adult mandible is because practitioners influence to think that the thick cortical plate counter diffusion of solution into the cancellous bone and, therefore, to the nerves supplying the pulps of the teeth.¹⁵

On the other side 103 patients out of 113 were pain free and 10 patients out of 113 were feeling pain during tooth extraction in male group. Again 79 patients out of 87 were pain free and 6 patients out of 87 were feeling pain during tooth extraction in female group.

CONCLUSION:

Infiltration technique provides an alternative approach to inferior alveolar nerve block technique during extraction of of Advance periodontitis of mandibular molars

CONFLICTS OF INTEREST:

The authors report no conflicts of interest.

REFERENCES:

1. Malamed S F. Handbook of Local Anesthesia. 6th ed. St Louis: Elsevier; 2013.
2. Milgrom P, Coldwell S E, Getz T, Weinstein P, Ramsay D S. Four dimensions of fear of dental injections. J Am Dent Assoc. 1997;128(6): 756-766. <https://doi.org/10.14219/jada.archive.1997.0301> PMID:9188235
3. Rood JP. The pressures created by inferior alveolar injections. Br Dent J. 1978; 144(9):280-282. <https://doi.org/10.1038/sj.bdj.4804079> PMID:274139
4. Rogers KB, Allen FF, Markiewicz S W. The effect of warming local anesthetic solutions prior to injection. Gen Dent. 1989;37(6):496-499.
5. Dworkin S F. Psychological considerations for facilitating anesthesia and sedation in dentistry. In: Dionne RA, Laskin D M, editors. Anesthesia and Sedation in the Dental Office. New York: Elsevier; 1986:15-28.
6. Kaufman E, Epstein JB, Naveh E, Gorsky M, Gross A, Cohen G. A survey of pain, pressure, and discomfort induced by commonly used oral local anesthesia injections. Anesth Prog. 2005; 52(4):122-127. [https://doi.org/10.2344/0003-3006\(2005\)52\[122:ASP\]2.0.CO;2](https://doi.org/10.2344/0003-3006(2005)52[122:ASP]2.0.CO;2)
7. Oulis C J, Vadiakas G P, Vasilopoulou A. The effectiveness of mandibular infiltration compared to mandibular block anesthesia in treating primary molars in children. Pediatr Dent J 1996; 18:301-5
8. Heller AA, Shankland WE. Alternative to the inferior alveolar nerve block anesthesia when placing mandibular dental implants posterior to the mental foramen. J Oral Implantol 2001; 27:127-33. [https://doi.org/10.1563/1548-1336\(2001\)027<0127:ATTIAN>2.3.CO;2](https://doi.org/10.1563/1548-1336(2001)027<0127:ATTIAN>2.3.CO;2)
9. Talesh KT, Solahaye-Kahnamouii S. Application of Crestal Anesthesia for Treatment of Class I Caries in Posterior Mandibular Teeth. J Dent Res 2011; 5:17-22.
10. Champan PJ. Postoperative pain control for outpatient oral surgery. J Endod 2003; 28:89-91.
11. Hussein R M, Muhammad D N, Omar O A. Comparison between infiltration and inferior alveolar nerve block anesthesia in extraction of non-vital mandibular posterior teeth. Zanco J. Med. Sci 2014; 18(3): 822-825. <https://doi.org/10.15218/zims.2014.0040>
12. Etoz1 O A, Erl N, Demirbas A E. Issupraperiosteal infiltration anesthesia safe enough to prevent inferior alveolar nerve during posterior mandibular implant surgery. Med Oral Patol Oral Cir Bucal 2011; 16:386-9. <https://doi.org/10.4317/medoral.16.e386> PMID:21196835

13. Madeira MC, Percinoto C, das Graças M, Silva M. Clinical significance of supplementary innervation of the lower incisor teeth: a dissection study of the mylohyoid nerve. Oral Surg Oral Med Oral Pathol 1998; 46:608-14. [https://doi.org/10.1016/0030-4220\(78\)90455-3](https://doi.org/10.1016/0030-4220(78)90455-3)
14. Pogrel MA, Smith R, Ahani R. Innervation of the mandibular incisors by the mental nerve. J Oral Maxillofac Surg 1997; 55:961-3. [https://doi.org/10.1016/S0278-2391\(97\)90070-7](https://doi.org/10.1016/S0278-2391(97)90070-7)
15. Sutton RN. The practical significance of mandibular accessory foramina. Aust Dent J 1994; 19:167-73. <https://doi.org/10.1111/j.1834-7819.1974.tb05034.x> PMID:4530720