

# The Role of Vitamin A, Vitamin C and Vitamin E for Chemoprevention of Oral Leukoplakia

Islam M<sup>1\*</sup>, Ali MN<sup>2</sup>, Anwar RB<sup>3</sup>, Asaduzzaman M<sup>4</sup>, Islam ASMA<sup>5</sup>, Hussain M<sup>6</sup>, Rahman DQB<sup>7</sup>

## AFFILIATION:

- DR. MOHIDUL ISLAM**<sup>1b</sup>  
BDS, Medical Officer  
Oral & Maxillofacial Surgery Department  
Bangabandhu Sheikh Mujib Medical University, Bangladesh
- DR. MIR NOWAZESH ALI**<sup>1b</sup>  
BDS, MS, PhD, Assistant Professor  
Oral & Maxillofacial Surgery Department  
Bangabandhu Sheikh Mujib Medical University, Bangladesh
- DR. REZWANA BINTE ANWAR**  
BDS, MS, PhD, Assistant Professor  
Department of Prosthodontics  
Bangabandhu Sheikh Mujib Medical University, Bangladesh
- DR. MD. ASADUZZAMAN**  
BDS, FCPS, Associate Professor  
Oral & Maxillofacial Surgery Department  
Bangabandhu Sheikh Mujib Medical University, Bangladesh
- DR. A. S. M. ARIFUL ISLAM**  
BDS, MS, Assistant Professor and Head  
Department of Oral and Maxillofacial Surgery  
Update Dental College and Hospital, Bangladesh
- DR. MAHBUB HUSSAIN**  
BDS, MS, Junior Consultant  
Sylhet MAG Osmani Medical College Hospital
- PROF. DR. QUAZI BILLUR RAHMAN**  
MD, PhD, Professor & Former Chairman  
Oral & Maxillofacial Surgery Department  
Bangabandhu Sheikh Mujib Medical University, Bangladesh

## Article info.

Received: 05 July 2023

Accepted: 12 August 2023

Volume: Vol-13, Issue-2, October 2023

DOI: <https://doi.org/10.3329/updcj.v13i2.68329>



© Authors retain copyright and grant the journal right of first publication with the work simultaneously licensed under Creative Commons Attribution License CC - BY 4.0 that allows others to share the work with an acknowledgment of the work's authorship and initial publication in this journal.

<https://creativecommons.org/licenses/by/4.0/>

**Publisher:** Update Dental College, Dhaka, Bangladesh

**Web:** [www.updatedentalcollege.edu.bd](http://www.updatedentalcollege.edu.bd)

**E-mail:** [updcj@hotmail.com](mailto:updcj@hotmail.com)



Scan QR code to access your article on UpDCJ BanglaJOL index

## \* Corresponding Author

**DR. MOHIDUL ISLAM**

BDS, Medical Officer

Oral & Maxillofacial Surgery Department

Bangabandhu Sheikh Mujib Medical University, Bangladesh

E-mail: [mohidul.bsmmu@yahoo.com](mailto:mohidul.bsmmu@yahoo.com)

<https://orcid.org/0009-0002-7326-7315>

Cell: +88 01716027855

## ABSTRACT:

**Introduction:** Oral leukoplakia is a prevalent oral mucosal lesion known to undergo malignant transformation, posing a significant public health concern worldwide, primarily attributable to tobacco use. This study aims to investigate the potential preventive effects of Vitamins A, C, and E on oral leukoplakia. We conducted a cross-sectional study at the Department of Oral & Maxillofacial Surgery, Bangabandhu Sheikh Mujib Medical University (BSMMU), Dhaka, Bangladesh, over a one-year period from March 2017 to March 2018.

**Methods: Study Population:** We enrolled a total of 43 patients diagnosed with oral leukoplakia attending the Outpatient Department (OPD) of the Oral & Maxillofacial Surgery Department. **Data Collection:** Patients were assessed at 6, 12, and 24-week intervals, during which data were collected using standardized data sheets. Lesion size was measured in square centimeters, and lesion color was recorded through photography. Adverse drug reactions were monitored based on patient complaints during follow-up. **Histopathological Evaluation:** Histopathological evaluations were performed both before the study and at the conclusion of the study to assess any changes in tissue characteristics. **Outcome Variables:** The primary outcome variables of interest were clinical response, histopathological findings, and complications associated with the treatment.

**Results:** The study population had a mean age of 44.95±10.42 years, with an age range from 22 to 60 years. The male-to-female ratio was 1.3:1. The average duration of the lesions was 14.81±4.82 months, with a range of 6 to 24 months. Lesions were most commonly located in the right buccal mucosa (41.9%), followed by the left buccal mucosa (27.4%). The mean initial lesion size was 4.08±1.95 cm<sup>2</sup>, ranging from 1 to 8 cm<sup>2</sup>. After 24 weeks, 11.63% of patients showed complete improvement. All patients initially presented with white lesions, with a reduction to 97.7% after 6 weeks, 88.4% after 12 weeks, and 69.8% after 24 weeks. Mild adverse drug reactions were reported in 11.7% of patients after 6 weeks and 2.3% after 12 and 24 weeks. Complete remission was observed in 11.6% of patients, and moderate improvement (41-90%) in 37.3%. Notably, one-third of patients experienced a significant color change in their lesions, and adverse drug reactions decreased during subsequent follow-up.

**Conclusion:** This cross-sectional study indicates potential benefits of Vitamin A, Vitamin C, and Vitamin E in mitigating oral leukoplakia symptoms, such as reduced lesion size and color improvement, with fewer adverse reactions observed. However, larger controlled trials are necessary to establish the definitive efficacy of this vitamin combination.

**KEY WORDS:** Oral leukoplakia, Vitamin A, Vitamin C and Vitamin E, Chemoprevention

## INTRODUCTION

Oral leukoplakia is defined as a white plaque that does not rub off from oral mucosa and cannot be characterized as any other definable lesion. Most cases of leukoplakia are noted as hyperkeratotic response to an irritant and are asymptomatic, but about 20% of leukoplakic lesions show evidence of dysplasia or carcinoma during first clinical recognition.<sup>1</sup>

However, some anatomic sites (floor of the mouth and ventral surface of the tongue) have rates of dysplasia or carcinoma as higher as 45%. There is no reliable correlation between clinical appearance and histopathological presence of dysplastic changes except that the possibility of epithelial dysplasia increases in leukoplakic lesions with interspersed red areas. In one study conducted by Silverman et al.<sup>2</sup> shows lesions with an erythroplakic component has a 23.4% malignant transformation rate, compared with a 6.5% rate for lesions that were homogenous.

Precancerous lesions could include a whole range of events leading to the development of malignancy, such as the formation of DNA adducts, micronuclei, and sister chromatid exchanges conventionally however, pathologist use the term "Premalignant lesion" for abnormal growth of tissue with altered nuclei, such as dysplasia and carcinoma in situ. A suggestion has been made to define premalignant lesions as "Atypical intraepithelial proliferation with varying degrees of architectural and nuclear changes."<sup>3</sup>

A prominent contributor to the onset and development of oral cancer is damage to DNA and other cellular molecules by reactive oxygen species. Tobacco use, the primary known risk factor for oral cancer and precancerous lesions, also increases oxidative stress therefore enhances the possibility of cancer-causing mutation, oxidation of signal transduction pathways that damage cells. Dietary micronutrients, such as vitamin E, vitamin C, beta carotene and lycopene, have potential chemoprevention property that can neutralize or block reactive oxygen species and protect against cellular damage.<sup>4</sup>

L-ascorbic acid (L-AA), the so-called vitamin C, is found in citrus fruits such as kiwi, strawberries, papaya, and mango. L-AA has antioxidizing properties and reacts with superoxide produced as a result of the cells normal metabolic processes; this inactivation of superoxide inhibits the formation of nitrosamines during protein digestion and helps avoid damage to DNA and cellular proteins.<sup>5</sup> L-AA toxicity does not occur, since vitamin is water-soluble

Alpha-Tocopherol (AT) is the commonest and most active form of vitamin E. It is found in plant oil, margarine, and green leaves.<sup>6,7</sup> Alpha-Tocopherol is an effective antioxidant at high levels of oxygen, protecting cellular membranes from lipidic peroxidation.<sup>8,9</sup>

There are strong clinical and investigational reasons for studying the use of systemic agents to leukoplakia. The high risk of transformation of dysplastic leukoplakia and the number of patients at high risk who are not helped by surgery provide the clinical basis for a trial of the chemopreventive approach. The broader rationale for this investigation rests on the relation of leukoplakia through field carcinogenesis to other tobacco related epithelial cancers of the aero digestive tracts. Excellent preclinical models are available for studying oral carcinogenesis and intervention in this process. Located in the oral cavity, leukoplakia can be monitored easily and relatively noninvasively. It therefore serve as an ideal in vivo human model for testing the potential of chemopreventive agents throughout this region. This study is proposed to evaluate the effectiveness and outcome of chemopreventive supplement such as vitamin A, vitamin C & vitamin E in treatment of oral leukoplakia.

## METHODS

This was an cross-sectional study carried out at Oral & Maxillofacial Surgery Department, Bangabandhu Sheikh Mujib Medical University (BSMMU), Shahbag, Dhaka-1000, Bangladesh from March 2017 to March 2018. Out-patients visiting the study place was used as the study population. The 43 consecutive patients diagnosed as oral leukoplakia were serve as cases. The research was carried out after obtaining written informed consents from all the patients. The main outcome variables were clinical response, histopathological findings and complication. Histopathologically diagnosed case of Leukoplakia and Indication for the treatment of Leukoplakia with

vitamin A, vitamin C & vitamin E were used as the inclusion criteria for this study. Vitamin A, vitamin C & vitamin E were given in combination on patients using following dosage:

Vitamin A (Cap. Ratinol Forte, Drug International Ltd.), 50,000 I.U., one capsule 4days in a week for six consecutive months.

Vitamin E (Cap. Ecap, Drug International Ltd.), 400 I.U., one capsule twice daily for six consecutive months.

Vitamin C (Tab. Ceevit DS, Square Pharmaceutical Ltd.), 500mg, one tablet twice daily for six consecutive months.

The exclusion criteria- Pregnant patients, Previously intake of large dose of vitamin A, History of oral cancer, Patients with Renal & Hepatic diseases, Hypervitaminosis patients.

**Procedure of collecting data:** Each patient for the study was evaluated at every 6th, 12th, 24th weeks interval and in every follow-up data was collected according to a pre designed data sheet. During every follow-up lesion size was evaluated by using calipers and a standard scale (Length x Width), Lesion colour was evaluated by photography, and adverse drug reaction was evaluated according to patients complain during follow up. Histopathological evaluation was obtained before study. The statistical analysis was carried out using the Statistical Package for Social Sciences version 23.0 for Windows (SPSS Inc., Chicago, Illinois, USA). Qualitative variables were expressed as frequencies, percentages. Quantitative variables were expressed as mean±standard deviation.

**Ethical implications:** Ethical clearance for the study was obtained from the institutional review board of BSMMU prior to the commencement of the study (IRB Certificate Number BSMMU/2017/3482). Permission for the study was taken from the department of oral and maxillofacial surgery, BSMMU. The aim and objectives of the study were explained to the study subjects in an easily understandable local language. Written informed consent of all the study subjects were taken free of duress and without exploiting any weakness of the subject. Assurance was given about their confidentiality and the freedom to withdraw them from the study at any time.

## RESULTS

**Table 1: Distribution of the study patients by demographic variables (n=43)**

Demographic variables n	Percent	
<b>Age (in years)</b>		
22-30	6	14.0
31-50	23	53.4
>50	14	32.6
Mean±SD	44.95	±10.42
Range (Min-max)	22	-60
<b>Sex</b>		
Male	24	55.8
Female	19	44.2

Table 1 shows demographic variables of the study patients, it was observed that more than half (53.4%) patients belonged to age 31-50 years. The mean age was found 44.95±10.42 years with ranged from 22 to 60 years. More than half (55.8%) patients were male.

**Table 2: Distribution of the study patients by duration of the lesion (n=43)**

Duration of the lesion (in month) n	Percent
6-12	44.1
13-18	32.7
19-24	23.2
Mean±SD	14.81 ±4.82
Range (Min-max)	6 -24

Table 2 shows lesion period of the study patients, it was observed that almost half (44.1%) patients belonged to lesion period 6-12 months. The mean lesion period was found 14.81±4.82 months with ranged from 6 to 24 months.

**Table 3: Distribution of the study patients by site of the lesion (n=43)**

Site of the lesion	n	Percent
Right alveolar mucosa	1	2.3
Dorsum of the tongue	1	2.3
Left buccal mucosa	12	27.9
Right side of the gingiva	3	7.0
Right buccal mucosa	18	41.9
Left side of the gingiva	6	14.0
Right lateral border of tongue	1	2.3
Left lateral border of tongue	1	2.3

Table 3 shows distribution of the study patients by site of the lesion, it was observed that 18(41.9%) patients had right buccal mucosa, 12(27.9%) in left buccal mucosa, and others are depicted in the above table.

**Table 4: Distribution of the study patients by initial lesion size (n=43)**

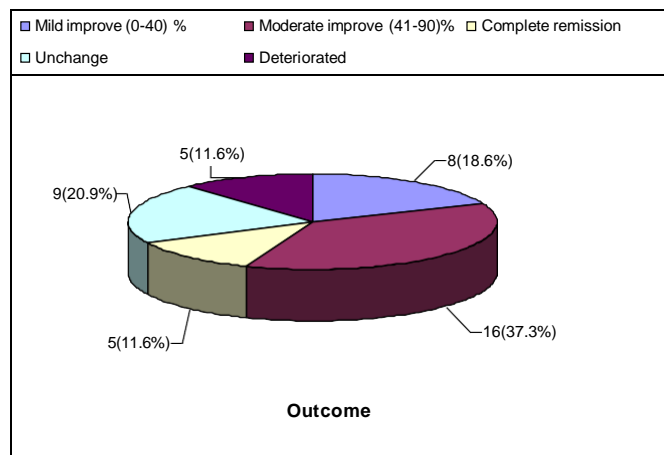
Initial lesion size (cm <sup>2</sup> )	n	Percent
Size at the time of diagnosis (cm <sup>2</sup> )		
1	1	2.3
2	10	23.2
2.5	3	7.0
3	5	11.6
3.5	2	4.7
4	7	16.3
4.5	1	2.3
6	9	20.9
7	2	4.7
8	3	7.0
Mean±SD	4.08 ±1.95	
Range (Min-max)	1.5 -8	

Table 4 shows distribution of the study patients by initial lesion size, it was observed that all most one fourth 10(23.2%) patient's lesion size were 2 cm<sup>2</sup>, 9(20.9%) patient's lesion size were 6 cm<sup>2</sup> and 7(16.3%) patient's lesion size were 4 cm<sup>2</sup>. The mean initial lesion size was found 4.08±1.95 cm<sup>2</sup> with ranged from 1 to 8 cm<sup>2</sup>

**Table 5: Distribution of the study patients by adverse drug reaction (n=43)**

Adverse Drug Reaction	n	Percent
<b>After 6 weeks of treatment</b>		
No Reaction	37	86.0
Mild Reaction	5	11.7
Moderate Reaction	1	2.3
<b>After 12 weeks of treatment</b>		
No Reaction	41	95.3
Mild Reaction	2	4.7
<b>After 24 weeks of treatment</b>		
No Reaction	42	97.7
Mild Reaction	1	2.3

Table 5 shows distribution of the study patients by adverse drug reaction, it was observed that after 6 weeks no adverse drug reaction was found in 37 patients(86.0%), after 12 weeks no adverse drug reaction was found in 41 patients(95.3%) and after 24 weeks adverse drug reaction was not found in 42 patients(97.7%). Others are depicted in the above table.

**Figure 1: Pie chart showing outcome of the study patients****Table 6: Comparison between outcome with duration (in month) (n=43)**

Outcome	Duration		
	n	Mean±SD	Range (min-max)
Complete remission	5	12.20±4.60	6 -18
Moderate improve	16	15.69±4.16	9 -20
Mild improve	8	15.38±4.24	10 -22
Unchange	9	16.40±4.77	12 -24
Deteriorated	5	19.00±3.61	15 -22

Complete remission was found in 5 patients, where their mean duration of disease was 12.20±4.60 months ranged from 6 to 18 months. Moderate improve (41-90%) was found in 16 patients and their mean duration of disease was 15.69±4.16 months with ranged from 9 to 20 months. Mild improve (0-40%) was observed in 8 patients and their mean duration of disease was 15.38±4.24 months with ranged from 10 to 22 months. Unchanged was found in 9 patients and their mean duration of disease was 16.40±4.77 months with ranged from 12 to 24 months. Deteriorated was found in 5 patients and their mean duration of disease was 19.00±3.61 months with ranged from 15 to 22 months.

**Table 7: Comparison between outcome with lesion size (n=43)**

Outcome	Lesion size		
	n	Mean±SD	Range (min-max)
Complete remission	5	2.40±0.89	1 -4
Moderate improve	16	2.25±1.23	1 -5
Mild improve	8	3.25±1.58	2 -6
Unchange	9	4.89±2.42	2 -8
Deteriorated	5	5.17±2.36	3 -7

Complete remission was found in 5 patients, where they had mean lesion size was 2.40±0.89 cm<sup>2</sup> ranged from 1 to 4 cm<sup>2</sup>. Moderate

improve (41-90%) was found in 16 patients and they had mean lesion size was  $2.25 \pm 1.23 \text{ cm}^2$  ranged from 1 to  $5 \text{ cm}^2$ . Mild improve (0-40%) was observed in 8 patients and they had mean lesion size was  $3.25 \pm 1.58 \text{ cm}^2$  ranged from 2 to  $6 \text{ cm}^2$ . Unchanged was found in 9 patients and they had mean lesion size was  $4.89 \pm 2.42 \text{ cm}^2$  ranged from 1 to  $8 \text{ cm}^2$ . Deteriorated was found in 5 patients and they had mean lesion size was  $5.17 \pm 2.36 \text{ cm}^2$  ranged from 3 to  $7 \text{ cm}^2$ .

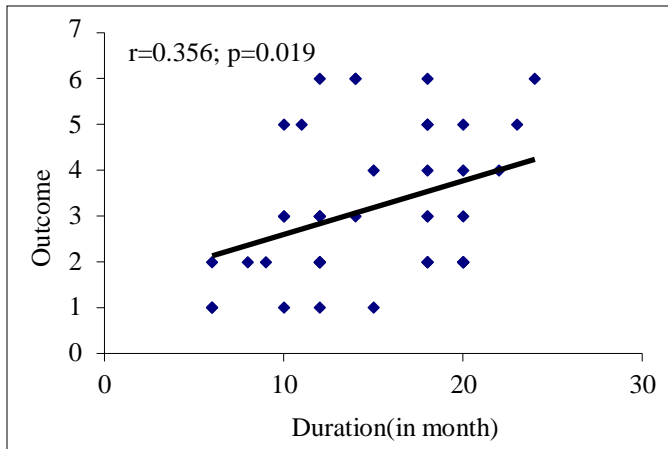


Figure 2: Scatter diagram showing positive significant correlation ( $r=0.356$ ;  $p=0.019$ ) between duration (in month) and outcome.

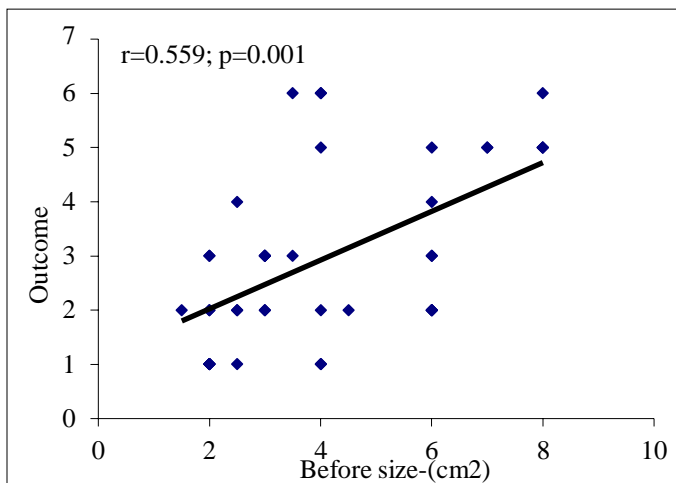


Figure 3: Scatter diagram showing positive significant correlation ( $r=0.559$ ;  $p=0.001$ ) between before size ( $\text{cm}^2$ ) and outcome

## DISCUSSION

This observational study was carried out with an aim to evaluate the response of Vitamin A, Vitamin C and Vitamin E in patient with oral Leukoplakia and to evaluate the duration for chemoprevention. A total of 43 patients with Leukoplakia reported to the OPD of oral & maxillofacial surgery department of Bangabandhu Sheikh Mujib Medical University, Shahbag, Dhaka-1000, Bangladesh, March 2017 to March 2018 were included in this study. Histopathologically diagnosed case of Leukoplakia and indication for the treatment of Leukoplakia with vitamin A, vitamin C & vitamin E were enrolled in this study. Pregnant patients, previously intake of large dose of vitamin A, history of oral cancer within the two years before the

study, patients with Renal & Hepatic diseases and hypervitaminosis patients were excluded from the study. The current study findings were explained and compared with previously published related studies.

In this present study, it was observed that 53.4% patients having leukoplakia age belonged to 31-50 years and the mean age was found  $44.95 \pm 10.42$  years with ranged from 22 to 60 years. Thomas et al.<sup>10</sup> found the mean age was 47.8 years, which is comparable with the present study. In another study Ribeiro et al.<sup>11</sup> mentioned that oral leukoplakia (OL) is more often found among older and elderly men and its prevalence increases with age advancement. It has been estimated that less than 1% of the affected men are younger than 30 years old and that the prevalence increases to 8.0% in male patients older than 70 years old and to 2% in female patients of 70 years or more. On the other hand, Jordan<sup>12</sup> found the mean age was 66.7 years, which is higher with the current study. Similarly, in another study Nagao et al.<sup>13</sup> found the median age was 65 years with ranged from 38–80 years, which is also higher with the current study. The higher mean age and age range obtained by the above authors maybe due to geographical variations, racial, ethnic differences and genetic causes may have significant influence on oral leukoplakia in their study subjects.

In this current study, it was observed that 55.8% patients were male, which indicates that oral leukoplakia is predominant in male subjects. Nagao et al.<sup>13</sup> study also showed male 54.3% and female 45.7%, which is consistent with the current study. Ribeiro et al.<sup>11</sup> OL is more often found among elderly men and the prevalence increases to 8% in male patients older than 70 years old and to 2% in female patients of 70 years or more, which is also similar with the present study. On the other hand, Thomas et al.<sup>10</sup> found 46.0% males and 54.0% female, which differ with the present study.

In this present study, it was observed that 44.1% patients belonged to lesion period 6-12 months and the mean lesion period was found  $14.81 \pm 4.82$  months with ranged from 6 to 24 months.

Regarding the site of the lesion, it was observed in this current study that more than one third 41.9% patients had lesion in right buccal mucosa followed by 27.9% in left buccal mucosa, 14.0% left side of the gingiva, 7.0% right side of the gingiva, 2.3% lesions were noted both in right alveolar mucosa and dorsum of the tongue, right and left lateral border of the tongue also showed 2.3%. The most common sites affected are the buccal mucosa, the labial mucosa and the alveolar mucosa<sup>14</sup>, although any mucosal surface in the mouth may be involved.<sup>15</sup>

In this current study, it was observed that 23.3% patient's lesion size was  $2 \text{ cm}^2$ , 20.9% patient's lesion size was  $6 \text{ cm}^2$  and 16.3% patient's lesion size was  $4 \text{ cm}^2$ . The mean initial lesion size was found  $4.08 \pm 1.95 \text{ cm}^2$  with ranged from 1 to  $8 \text{ cm}^2$ . For solitary lesions, the primary site, and for multiple lesions, the number of involved sites were observed by Nagao et al.<sup>13</sup> and they found  $<2 \text{ cm}$  had in 61.0% patients, 2 -  $4 \text{ cm}$  30.0% and  $>4 \text{ cm}$  9.0%.

Regarding the treatment outcome, lesion stage of initial size and during subsequent follow up it was observed in this study that 11.63% patients had complete improvement after 24 weeks. Epstein and Gorsky<sup>16</sup> study reported that all 26 patients using topical 0.05% tretinoin gel four times a day for 3.5 years showed signs of clinical improvement. However, 27% showed total remission and 40% of these patients had recurrence of the disease after the discontinuation of the treatment. In Dimery et al.<sup>17</sup> study, patients received a fixed



dose of 13-cRA (10 mg/day) plus an escalating dose (beginning at 800 IU/day, until 2000 IU/day) for 4 months. Seventy-one percent of OL patients had complete clinical responses.

Regarding the color of the lesion, it was observed in this current study that 100.0% in initial stage, 97.7% after 6 weeks, 88.4% after 12 weeks and 69.8% after 24 weeks.

The systemic use of retinoids may lead to severe adverse effects, especially in individuals who need high doses of medication or long-term treatment (Manigandan and Hemalatha.<sup>18</sup> The toxicity seems to be dose-dependent and recurrences are common after the discontinuation of its use.<sup>19,20</sup> Therefore, a close follow-up of these patients is mandatory. On the other hand, the topical administration of retinoids allows the application of higher concentrations of the drug directly on the lesion but with less adverse effects.<sup>16,19,21</sup>

Regarding the adverse drug reaction, it was observed in this study that after 6 weeks mild reaction was found 11.7% and moderate reaction in 2.3%. After 12 weeks adverse drug reaction was found 4.7% mild and after 24 weeks adverse drug reaction was found 2.3% mild, which indicates that adverse drug reaction reduced in subsequent follow-up. Kotecha et al.<sup>22</sup> study found to have a decreased number of polyps after six months of treatment without other laboratory abnormalities and minimal adverse effects observed by Cruz-Correa et al.<sup>23</sup> The adverse effects were mostly found among smokers when beta-carotene was taken in excess of 20 mg/day, health benefits are reported in observational diet studies.<sup>24</sup> Fernandes<sup>25</sup>; Gorsky and Epstein<sup>19</sup> studies reported that nonsurgical treatment may also be considered for the management of Oral Leukoplakia (OL). This modality offers minimal adverse effects to patients, especially for patients with widespread OL that involves a large area of the oral mucosa or patients with medical problems.<sup>26</sup>

Mouli et al.<sup>27</sup> recommended use of Vitamin-E as an antioxidant in oral lesions. Vitamin-E can inhibit reactions of the tobacco specific nitrosamine (carcinogens) which undergo specific activation and detoxification process. Antioxidants such as  $\beta$  carotene, provitamin A, vitamin-C, vitamin-E, zinc, selenium and spirulina are believed to have a preventive role against oral cancer.<sup>28</sup>

In this present study, it was observed that complete improvement was found 11.6% and moderate improvement (41-90%) was found 37.3%. A study conducted by Olson<sup>29</sup> reported that complete remission of OL was observed in 57% of patients who received vitamin A about 2,00,000 IU. In another study patients with OL treated by beta-carotene (180 mg/week) plus vitamin A (100,000 IU/week) showed significant results.<sup>30</sup> In another study Benner et al.<sup>31</sup> evaluated the toxicity and efficacy of AT in 43 patients with OL in use of 400 IU twice daily for 24 weeks and observed that 23.0% patients had complete clinical remission of lesion and 23.0% had a partial clinical response. Nine (21%) had histologic responses (complete reversal of dysplasia to normal epithelium).

L-Ascorbic Acid (Vitamin C) has antioxidantizing properties and reacts with superoxide produced as a result of the cells normal metabolic processes; this inactivation of superoxide inhibits the formation of nitrosamines during protein digestion and helps avoid damage to DNA and cellular proteins.<sup>5</sup> L-AA toxicity does not occur, since vitamin is water-soluble and a decrease in absorption efficiency occurs when consumption exceeds 180 mg/day.<sup>32</sup>

Study done by Rai et al.<sup>33</sup> have proved that antioxidants such as Vitamin-C and Vitamin-E may be utilized in oral Lichen planus patients to counteract free radical mediated cell disturbances. Maheswari<sup>34</sup>

highlighted the role of Vitamin-E in the treatment of leukoplakia. Antioxidant combinations (Vitamin A, E, and C) had proved to be most effective with maximum clinical resolution 90% recorded<sup>35</sup> and regression of dysplasia recorded as 97.5%.<sup>36</sup> Vikas et al.<sup>37</sup> study showed that among 43 patients with oral leukoplakia who took 400 IU of vitamin E twice daily for 24wks, 46% had clinical responses and 21.0% had histological responses. The medication was well accepted, without any toxicity, and with good compliance. Rai et al.<sup>33</sup> reported in his study that antioxidant defenses (vitamin-E and C) are compromised and oxidative stress is increased in patients with oral cancer. A feeble antioxidant defense process makes the mucosal cells more accessible to the cytotoxic effect of reactive oxygen species. This creates in intracellular situation more favourable for DNA damage and disease progression. So, antioxidant supplement (vitamin C and E) may have role in oral cancer patients. Maher et al.<sup>38</sup> evaluated the role of multiple micronutrients consisting of retinol, vitamin-E, vitamin-D, vitamin-B complex and some minerals in the management of OSMF and reported clinical improvement. Other work has indicated a possibly beneficial role for supplemental vitamin-E in diabetes based on lowered serum levels of glycosylated hemoglobin and triglyceride.<sup>39</sup> Supplemental vitamin-E at a dose of 60-800 ID/day reportedly improves immune function in elderly subjects<sup>40</sup> while a single dose of 1g helped to prevent oxidative damage of DNA.<sup>41</sup>

In this present study it was observed that the complete remission was found in 5 patients, where their mean duration of disease was 12.20 $\pm$ 4.60 months ranged from 6 to 18 months. Moderate improve (41-90%) was found in 16 patients and their mean duration of disease was 15.69 $\pm$ 4.16 months with ranged from 9 to 20 months. Mild improves (0-40%) was observed in 8 patients and their mean duration of disease was 15.38 $\pm$ 4.24 months with ranged from 10 to 22 months. Unchanged was found in 9 patients and their mean duration of disease was 16.40 $\pm$ 4.77 months with ranged from 12 to 24 months. Deteriorated was found in 5 patients and their mean duration of disease was 19.00 $\pm$ 3.61 months with ranged from 15 to 22 months. The above findings indicate that improvement was observed in early duration of disease suffering and deteriorated & unchanged were found in prolonged duration of disease. Therefore it can be mentioned that vitamin A (100000 IU orally twice a week), vitamin C (Ceevit DS; 1000mg/day) and vitamin E (800mg/day) had significant role for chemoprevention of oral leukoplakia in early stage of the disease i.e. early duration of the disease.

Gaeta et al.<sup>42</sup> study concluded that 71% of patient showed clinical remission or marked improvement. Nagao et al.<sup>13</sup> reported that the primary endpoint was clinical remission at 1-year and the likelihood of malignant transformation during a 5-year follow-up period as a secondary endpoint. The overall clinical response rate in the experimental arm was 17.4% and 4.3% in the placebo arm ( $p > 0.05$ ). In another recent study, ingestion of oral curcumin at 500 mg/day along with prednisone was associated with clinical and endoscopic remission in a 60-year-old woman with a 17-year history of left-sided ulcerative colitis and enteropathic arthropathy.<sup>43</sup>

Ribeiro et al.<sup>11</sup> study found complete remission was observed in 57.0% of patients that received vitamin A. The administered doses of vitamin A did not produce any detectable adverse effects during the trial period. In the placebo group, 7 patients (21.0%) formed new OL; whereas no new OL developed in the vitamin A group over the 6 months.<sup>30</sup> In an additional study from these same authors, patients

with OL were divided into three groups receiving: group 1, beta-carotene (180 mg/week); group 2, beta-carotene (180 mg/week) plus vitamin A (100,000 IU/week), and group 3 placebo, for 6 months. Remission of OL in group 1, (14.8%) and group 2 (27.5%) differed significantly from that seen in group 3 (3%). During the trial period, all patients continued to chew tobacco-containing betel quid's.<sup>30</sup> In this study it was observed that the complete remission was found in 5 patients, where they had mean lesion size was  $2.40 \pm 0.89$  cm<sup>2</sup> ranged from 1 to 4 cm<sup>2</sup>. Moderate improve (41-90%) was found in 16 patients and they had mean lesion size was  $2.25 \pm 1.23$  cm<sup>2</sup> ranged from 1 to 5 cm<sup>2</sup>. Mild improve (0-40%) was observed in 8 patients and they had mean lesion size was  $3.25 \pm 1.58$  cm<sup>2</sup> ranged from 2 to 6 cm<sup>2</sup>. Unchanged was found in 9 patients and they had mean lesion size was  $4.89 \pm 2.42$  cm<sup>2</sup> ranged from 2 to 8 cm<sup>2</sup>. Deteriorated was found in 5 patients and they had mean lesion size was  $5.17 \pm 2.36$  cm<sup>2</sup> ranged from 3 to 7 cm<sup>2</sup>, which specify that the improvement was more common in small lesion size, whereas deteriorated & unchanged were found large lesion size. In this current series it was observed that there was a positive significant correlation ( $r=0.356$ ;  $p=0.019$ ) between duration (in month) with result. In this study it was observed that there was a positive significant correlation ( $r=0.559$ ;  $p=0.001$ ) between previous size (cm<sup>2</sup>) and result. Vitamin A legislation result in a significant remission of oral leukoplakia without any side effects of prolonged vitamin A supplementation.

#### CONCLUSION:

This study was undertaken to find out the role of Vitamin A, Vitamin C and Vitamin E in preventing oral leukoplakia. Most of the patients having leukoplakia aged between 31-50 years and male predominant. Right buccal mucosa and left buccal mucosa was the most common site of the lesion. Nearly one third patients had significant color changed of the lesion and adverse drug reaction reduced in subsequent follow-up. Over all more than two third patients had improved; however, five patients had complete remission. There are numerous chemo preventive agents present in our daily diet which exert their anti-mutagenic action to routinely exposed mutagens. These agents might offer cure for malignancy and reversal of premalignancy in a specific concentration. Few limitations of the study were observed, study population was selected from one selected hospital in Dhaka city, so that the results of the study may not be reflect the exact picture of the country, very short period of time, small sample size was also a limitation of the present study. Therefore, in future further study may be under taken with large sample size.

#### RECOMMENDATION

The vitamins and other micronutrients have attracted the attention of the scientific community in recent decades, and it has become clear that they play an important role in the etiology of many diseases, including cancer. With respect to cancer, the results obtained so far are not conclusive but are optimistic. The results from ongoing clinical trials will provide a deeper understanding of Vitamin A, C and E's therapeutic potential and will help to place these fascinating molecules at the fore front of novel therapeutics. To understand the role of vitamins in the prevention and treatment of cancer, more studies are needed to clarify the mechanism of action.

**CONFLICT OF INTEREST:** The authors declare no conflict of interest.

**FUNDING:** This research received no external funding.

**DATA AVAILABILITY STATEMENT:** The data presented in this study are available on reasonable request from the corresponding author.

#### REFERENCES:

- Axéll T, Pindborg JJ, Smith CJ, Van der Waal I, an International Collaborative Group on Oral White Lesions. Oral white lesions with special reference to precancerous and tobacco-related lesions: conclusions of an international symposium held in Uppsala, Sweden, May 18-21 1994. *Journal of oral pathology & medicine*. 1996 Feb;25(2):49-54. <https://doi.org/10.1111/j.1600-0714.1996.tb00191.x> PMID:8667255
- Kaugars GE, Silverman Jr S, Lovas JG, Brandt RB, Riley WT, Dao Q, Singh VN, Gallo J. A clinical trial of antioxidant supplements in the treatment of oral leukoplakia. *Oral Surgery, Oral Medicine, Oral Pathology*. 1994 Oct 1;78(4):462-8. [https://doi.org/10.1016/0030-4220\(94\)90039-6](https://doi.org/10.1016/0030-4220(94)90039-6) PMID:7800378
- Rywin AM. Terminology of premalignant lesions in light of the multistep theory of carcinogenesis. *Human pathology*. 1984 Sep;15(9):806-7. [https://doi.org/10.1016/S0046-8177\(84\)80139-2](https://doi.org/10.1016/S0046-8177(84)80139-2) PMID:6469234
- Naidu KA. Vitamin C in human health and disease is still a mystery? An overview. *Nutrition journal*. 2003 Dec;2(1):1-0. <https://doi.org/10.1186/1475-2891-2-7> PMID:14498993 PMCID:PMC201008
- Frei B, England L, Ames BN. Ascorbate is an outstanding antioxidant in human blood plasma. *Proceedings of the National Academy of Sciences*. 1989 Aug 1;86(16):6377-81. <https://doi.org/10.1073/pnas.86.16.6377> PMID:2762330 PMCID:PMC297842
- Burton GW, Traber MG. Vitamin E: antioxidant activity, biokinetics, and bioavailability. *Annual review of nutrition*. 1990 Jul;10(1):357-82. <https://doi.org/10.1146/annurev.nu.10.070190.002041> PMID:2200468
- Azzi A, Ricciarelli R, Zingg JM. Non-antioxidant molecular functions of  $\alpha$ -tocopherol (vitamin E). *FEBS letters*. 2002 May 22;519(1-3):8-10. [https://doi.org/10.1016/S0014-5793\(02\)02706-0](https://doi.org/10.1016/S0014-5793(02)02706-0) PMID:12023009
- Horwitt MK. Vitamin E: a reexamination. *The American Journal of Clinical Nutrition*. 1976 May 1;29(5):569-78. <https://doi.org/10.1093/ajcn/29.5.569> PMID:773168
- Herrera E, Barbas C. Vitamin E: action, metabolism and perspectives. *Journal of physiology and biochemistry*. 2001 Mar;57(1):43-56. <https://doi.org/10.1007/BF03179812>
- Thomas P, Wu J, Dhillon V, Fenech M. Effect of dietary intervention on human micronucleus frequency in lymphocytes and buccal cells. *Mutagenesis*. 2011 Jan;26(1):69-76. <https://doi.org/10.1093/mutage/geq072> PMID:21164185
- Ribeiro AS, Salles PR, da Silva TA, Mesquita RA. A review of the nonsurgical treatment of oral leukoplakia. *International journal of dentistry*. 2010 Feb 23;2010. <https://doi.org/10.1155/2010/186018> PMID:20339486 PMCID:PMC2836849
- Jordan VC. Estrogen, selective estrogen receptor modulation, and coronary heart disease: something or nothing. *Journal of the National Cancer Institute*. 2001 Jan 3;93(1):2-4. <https://doi.org/10.1093/jnci/93.1.2> PMID:11136828
- Nagao T, Warnakulasuriya S, Nakamura T, Kato S, Yamamoto K, Fukano H, Suzuki K, Shimozato K, Hashimoto S. Treatment of oral leukoplakia with a low-dose of beta-carotene and vitamin C supplements: A randomized controlled trial. *International Journal of Cancer*. 2015 Apr;136(7):1708-17. <https://doi.org/10.1002/ijc.29156> PMID:25156040
- Tanaka T, Tanaka M, Tanaka T. Oral carcinogenesis and oral cancer chemoprevention: a review. *Pathology research international*. 2011 May 22;2011. <https://doi.org/10.4061/2011/431246> PMID:21660266 PMCID:PMC3108384
- Greenberg MS, Glick M. *Burket's oral medicine diagnosis & treatment (10th ed.)*. Hamilton, Ont.: BC Decker, 2003;87-105

16. Epstein JB, Gorsky M. Topical application of vitamin A to oral leukoplakia: A clinical case series. *Cancer: Interdisciplinary International Journal of the American Cancer Society*. 1999 Sep 15;86(6):921-7. [https://doi.org/10.1002/\(SICI\)1097-0142\(19990915\)86:6<921::AID-CNCR5>3.0.CO;2-6](https://doi.org/10.1002/(SICI)1097-0142(19990915)86:6<921::AID-CNCR5>3.0.CO;2-6)
17. Dimery IW, Hong WK, Lee JJ, Guillory-Perez C, Pham F, Fritsche Jr HA, Lippman SM. Phase I trial of alpha-tocopherol effects on 13-cis-retinoic acid toxicity. *Annals of Oncology*. 1997 Jan 1;8(1):85-9. <https://doi.org/10.1023/A:1008209525671> PMID:9093712
18. Manigandan T, Hemalatha VT. Insight of various medical management of oral leukoplakia. *Biomedical and Pharmacology Journal*. 2015 Oct 25;8(October Spl Edition):393-401. <https://doi.org/10.13005/bpi/710>
19. Gorsky M, Epstein JB. The effect of retinoids on premalignant oral lesions: focus on topical therapy. *Cancer*. 2002 Sep 15;95(6):1258-64. <https://doi.org/10.1002/cncr.10874> PMID:12216093
20. Lodi G, Sardella A, Bez C, Demarosi F, Carrassi A. Systematic review of randomized trials for the treatment of oral leukoplakia. *Journal of dental education*. 2002 Aug;66(8):896-902. <https://doi.org/10.1002/j.0022-0337.2002.66.8.tb03558.x> PMID:12214837
21. Pimenta FJ, Cordeiro GT, Pimenta LG, Viana MB, Lopes J, Gomez MV, Aldaz CM, De Marco L, Gomez RS. Molecular alterations in the tumor suppressor gene WWOX in oral leukoplakias. *Oral oncology*. 2008 Aug 1;44(8):753-8. <https://doi.org/10.1016/j.oraloncology.2007.08.019> PMID:18061530 PMID:PMC4143237
22. Kotecha R, Takami A, Espinoza JL. Dietary phytochemicals and cancer chemoprevention: a review of the clinical evidence. *Oncotarget*. 2016 Aug 9;7(32):52517. <https://doi.org/10.18632/oncotarget.9593> PMID:27232756 PMID:PMC5239570
23. Cruz-Correa M, Shoskes DA, Sanchez P, Zhao R, Hyland LM, Wexner SD, Giardiello FM. Combination treatment with curcumin and quercetin of adenomas in familial adenomatous polyposis. *Clinical Gastroenterology and Hepatology*. 2006 Aug 1;4(8):1035-8. <https://doi.org/10.1016/j.cgh.2006.03.020> PMID:16757216
24. Warnakulasuriya S, Johnson NW, Van der Waal I. Nomenclature and classification of potentially malignant disorders of the oral mucosa. *Journal of oral pathology & medicine*. 2007 Nov;36(10):575-80. <https://doi.org/10.1111/j.1600-0714.2007.00582.x> PMID:17944749
25. Fernandes G. Beta-carotene supplementation: friend or foe?. *The Journal of laboratory and clinical medicine*. 1997 Mar 1;129(3):285-7. [https://doi.org/10.1016/S0022-2143\(97\)90175-X](https://doi.org/10.1016/S0022-2143(97)90175-X) PMID:9042812
26. Hammersley N, Ferguson MM, Rennie JS. Topical bleomycin in the treatment of oral leukoplakia: a pilot study. *British Journal of Oral and Maxillofacial Surgery*. 1985 Aug 1;23(4):251-8. [https://doi.org/10.1016/S0266-4356\(18\)30307-3](https://doi.org/10.1016/S0266-4356(18)30307-3) PMID:2412577
27. Chandra Mouli PE, Senthil B, Parthiban S, Malarvizhi AE, Priya R, Subha R. Antioxidants and its role in Oral Cancer-a review. *Indian J Sci*. 2012;1:113-5.
28. IqubAl MA, KhAn M, KuMAr P, KuMAr A, AjAl K. Role of vitamin E in prevention of oral cancer- a review. *Journal of Clinical and Diagnostic Research: JCDR*. 2014 Oct;8(10):ZE05. <https://doi.org/10.7860/JCDR/2014/9166.4958> PMID:25478472 PMID:PMC4253290
29. Olson JA. Carotenoids and human health. *Archivos Latinoamericanos de Nutrición*. 1999 Sep 1;49(3 Suppl 1):7S-11S.
30. Stich HF, Hornby AP, Mathew B, Sankaranarayanan R, Nair MK. Response of oral leukoplakias to the administration of vitamin A. *Cancer letters*. 1988 May 1;40(1):93-101. [https://doi.org/10.1016/0304-3835\(88\)90266-2](https://doi.org/10.1016/0304-3835(88)90266-2) PMID:3370632
31. Benner SE, Winn RJ, Lippman SM, Poland J, Hansen KS, Luna MA, Hong WK. Regression of oral leukoplakia with  $\alpha$ -tocopherol: a community clinical oncology program chemoprevention study. *JNCI: Journal of the National Cancer Institute*. 1993 Jan 6;85(1):44-7. <https://doi.org/10.1093/jnci/85.1.44> PMID:8416256
32. Levine M, Conry-Cantilena C, Wang Y, Welch RW, Washko PW, Dhariwal KR, Park JB, Lazarev A, Graumlich JF, King J, Cantilena LR. Vitamin C pharmacokinetics in healthy volunteers: evidence for a recommended dietary allowance. *Proceedings of the National Academy of Sciences*. 1996 Apr 16;93(8):3704-9. <https://doi.org/10.1073/pnas.93.8.3704> PMID:8623000 PMID:PMC39676
33. Rai B, Kharb S, Jain R, Anand SC. Salivary vitamin E and C in lichen planus. *Gomal Journal of Medical Sciences*. 2008;6(2):1-5.
34. Maheswari U. Treatment of oral leukoplakia with antioxidants-a systematic review. *Int J Pharm Biol Sci*. 2013 Oct;4:33-41
35. Kaugars GE, Silverman Jr S, Lovas JG, Thompson JS, Brandt RB, Singh VN. Use of antioxidant supplements in the treatment of human oral leukoplakia review of the literature and current studies. *Oral Surgery, Oral Medicine, Oral Pathology, Oral Radiology, and Endodontology*. 1996 Jan 1;81(1):5-14. [https://doi.org/10.1016/S1079-2104\(96\)80139-9](https://doi.org/10.1016/S1079-2104(96)80139-9) PMID:8850475
36. Barth TJ, Zöller J, Kübler A, Born IA, Osswald H. Redifferentiation of oral dysplastic mucosa by the application of the antioxidants beta-carotene, alpha-tocopherol and vitamin C. *International Journal for Vitamin and Nutrition research. Internationale Zeitschrift für Vitamin-und Ernährungsforschung. Journal International de Vitaminologie et de Nutrition*. 1997 Jan 1;67(5):368-76.
37. Vikas F, Shailee F, Rajeev KS, Manoj KG. Oral Cancer and Prevention. *International Journal of Pharmaceutical Science Invention*, 2013; 2: 16-20.
38. Maher R, Aga P, Johnson NW, Sankaranarayanan R, Warnakulasuriya S. Evaluation of multiple micronutrient supplementation in the management of oral submucous fibrosis in Karachi, Pakistan, 2009; 41-47. <https://doi.org/10.1080/01635589709514499> PMID:8970180
39. Jain SK, Basu TK, Temple NJ, Garg, M.L. vitamin E and diabetes in Antioxidants in Human Health and Disease. Wallingford, Oxon, UK. CAB International, 199; 15: 1-64.
40. Meydani SN, Meydani M, Blumberg JB, Leka LS, Siber G, Loszewski R, Thompson C, Pedrosa MC, Diamond RD, Stollar BD. Vitamin E supplementation and in vivo immune response in healthy elderly subjects: a randomized controlled trial. *Jama*. 1997 May 7;277(17):1380-6. <https://doi.org/10.1001/jama.277.17.1380> PMID:9134944
41. Panayiotidis M, Collins AR. Ex vivo assessment of lymphocyte antioxidant status using the comet assay. *Free Radical Research*. 1997 Jan 1;27(5):533-7. <https://doi.org/10.3109/10715769709065793> PMID:9518069
42. Gaeta GM, Gombos F, Femiano F, Battista C, Minghetti P, Montanari L, Satriano RA, Argenziano G. Acitretin and treatment of the oral leukoplakias. A model to have an active molecules release. *Journal of the European Academy of Dermatology and Venereology*. 2000 Nov;14(6):473-8. <https://doi.org/10.1046/j.1468-3083.2000.00155.x> PMID:11444269
43. Lahiff C, Moss AC. Curcumin for clinical and endoscopic remission in ulcerative colitis. *Inflammatory Bowel Diseases*. 2011 Jul 1;17(7):E66. <https://doi.org/10.1002/ibd.21710> PMID:21484966



## CITE THIS ARTICLE

Islam M, Ali MN, Anwar RB, Asaduzzaman M, Islam ASMA, Hussain M, Rahman DQB. The Role of Vitamin A, Vitamin C and Vitamin E for Chemoprevention of Oral Leukoplakia. *Update Dent. Coll. j* [Internet]. [cited 2023 Oct. 7];13(2):23-29. Available from: <https://www.banglajol.info/index.php/UpDCJ/article/view/68329>

Website: <https://www.banglajol.info/index.php/UpDCJ>