

Infantile bullous pemphigoid: A Rare immunobullous disease where tzanck test is a valuable diagnostic aid

Md Mostaque Mahmud, Sanchita Biswas, Debatosh Paul

Article Info

Department of Dermatology & Venereology, Bangabandhu Sheikh Mujib Medical University, Dhaka (MMM); Dhaka National Medical College, Dhaka, (SB); Department of Laboratory Medicine, Bangabandhu Sheikh Mujib Medical University, Dhaka (DP)

For Correspondence:
Md. Mostaque Mahmud
Email: drmostq@yahoo.com

Received: 18 September 2021
Accepted: 30 November 2021
Available Online: 01 February 2022

ISSN: 2224-7750 (Online)
2074-2908 (Print)

DOI: <https://doi.org/10.3329/bsmmuj.v15i1.58430>

Keywords: Bullous pemphigoid, Tzanck test, Autoimmune bullous disease

Cite this article:

Mahmud MM, Biswas S, Paul D. Infantile bullous pemphigoid: A rare immunobullous disease where tzanck test is a valuable diagnostic aid. *Bangabandhu Sheikh Mujib Med Univ J.* 2022; 15(1): 57-60

Copyright:

The copyright of this article is retained by the author(s) [Attribution CC-BY 4.0]

Available at:

www.banglajol.info

A Journal of Bangabandhu Sheikh Mujib Medical University, Dhaka, Bangladesh



Presentation of Case

A 6-month-old boy of a non-atopic and non-consanguineous parents' presented with generalized vesiculobullous lesions that had a tendency to heal with hypopigmented patches for 2 months. According to his parents' statements, he was reasonably well 2 months ago when he developed some blisters that remained intact for 1 to 2 days before rupture. Then the lesions became healed without scarring and new blisters appeared after that. They also stated that the boy became restless and tried to scratch the affected area while new eruptions appeared. There was no history of trauma or taking any offending drug. On examination of integumentary system, there were multiple tense bullae mainly on the extremities and trunk with some erosion, crusted lesions and many hypopigmented healed patches. His mucous membrane, nails and hair distribution were normal. No other systemic abnormalities were found. Nickolsky sign and bullae spreading sign were both negative. Clinically the boy was diagnosed as a case of infantile bullous pemphigoid. With those blisters patients was consulted with several physicians and had taken different courses of oral and topical antibiotics and anti scabetics but there was no response. The patient was vaccinated as per EPI schedule. There was no history of vesiculo-bullous type of lesion in any step of his vaccination schedule. The patient was hospitalized for further evaluation and proper management. After confirmation of infantile BP the patient was treated with oral prednisolone 1mg/kg body weight and oral antihistamine and the condition was improving clinically.

Clinical diagnosis: Infantile bullous pemphigoid

Tzanck test procedure and findings:

Prof. Debatosh Paul: With consent of parent and using proper aseptic measures Tzanck

smear was taken in a cleaned glass slide from a fresh intact bullae (showed in picture). Two smears were taken in two slides from scraped material at the base of the bullae. The slides were sent to the department of Laboratory Medicine for examination. The slides were dried properly and stained with Giemsa and examined under light microscope. There were many eosinophils detected in both slides. There was no acantholytic keratinocyte and no other type of blood cell was found. So the Tzanck test report was in favor of bullous pemphigoid.

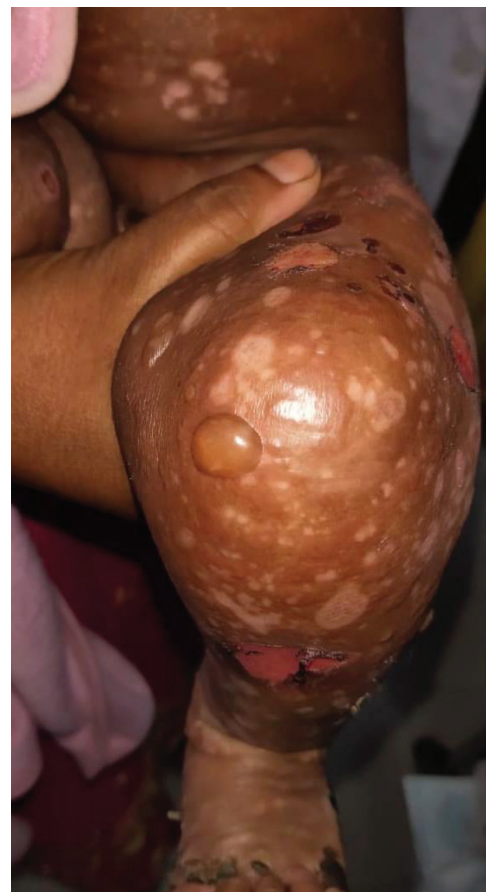

Figure - 1: A tense bullae on knee joint

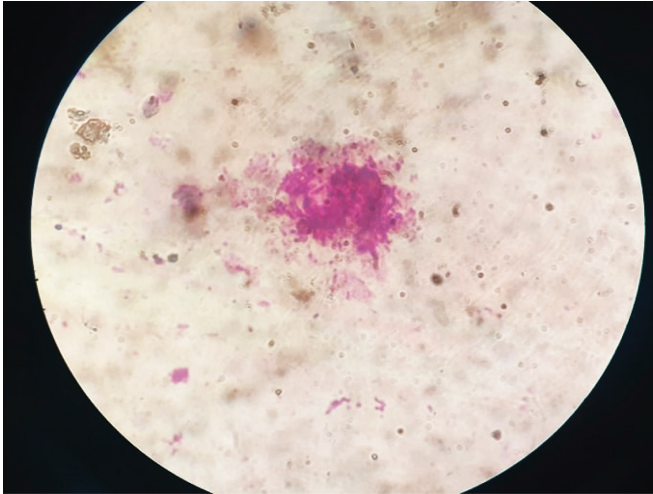


Figure - 2: Eosinophil in Tzanck smear

Tzanck test diagnosis: Bullous pemphigoid

Discussion

Differential diagnosis:

Chronic bullous disease of childhood (CBDC)

Chronic bullous disease of childhood is the most commonly occurring acquired autoimmune bullous disease in children. The age of onset of CBDC is 2-5 years and appearance of bullae in perigenital area, more chance of oral involvement and presents as a "cluster of jewel" pattern that clinically make it different from bullous pemphigoid and dermatitis herpetiformis. The course of CBDC is recurrent and relapsing. It is well responsive with dapsone therapy and usually remission occurs within puberty. Histopathology and direct immunofluorescent (DIF) test is required to confirm the diseases.^{1,2,3}

Dermatitis Herpetiformis (DH):

Dermatitis herpetiformis (DH) is a chronic pruritic vesiculobullous disease associated with gluten-sensitive enteropathy. DH is presented as chronic and recurrent intensely pruritic symmetrically distributed polymorphic skin lesions preferably on extensor parts of extremities, back and buttocks. The features of gluten sensitivity in childhood include persistent diarrhea, failure to thrive, abdominal pain, and vomiting and other signs of malabsorption. Lesional skin biopsy for histopathology and perilesional skin biopsy for direct immunofluorescent (DIF) study is the confirmatory test for DH. Some serological test like IgG-anti gliadin, IgA-tissue transglutaminase (anti-tTGase) and IgA anti endomysial antibody can substantiate the diagnosis. Small intestinal villous atrophy and duodenitis are the findings of celiac disease in endoscopic biopsy. Presence of neutrophil in tzanck

smear is pathognomonic diagnostic feature. DH is different from BP and CBDC by its clinical presentation, serological test and DIF.^{4,5,6}

Epidermolysis bullosa:

Epidermolysis bullosa (EB) is a group of inherited bullous disease characterized by skin fragility and mucocutaneous blister formation. Onset of disease manifestation is usually at birth and inducible by minimal trauma. The phenotypic spectrum of EB is broad, from mild skin fragility to severe extracutaneous involvement with various morbidity and mortality. Over 30 subtypes of EB are categorized into four major types based on the level of splitting within the skin and with genetic abnormality: EB simplex, junctional EB, dystrophic EB and Kindler EB. Genetic mutations in 16 different genes specially the genes encoding keratin 5 and or 14 have been found in EB, that proteins have key role in cellular integrity and adhesion. EB differs from BP and DH clinically by its early onset of nonpruritic flaccid and tense bullae with extra cutaneous manifestation. Histopathological study can determine the level of skin cleavage but no findings in DIF and in Tzanck test. Genetic analysis and electron microscopy is required to confirm EB with particular types. There is no curative treatment of EB. Wound care and minimization of trauma and infection is the way of management.^{7,8}

Hematological, Histopathological and DIF findings:

Prof. Debatosh Paul: Eosinophil count was higher than normal range in venous blood of the patient. Biopsy of lesional skin was showed there was subepidermal focal blister and eosinophilic infiltration on upper dermis. That report favors the clinical diagnosis and Tzanck test report BP. In direct immunofluorescence (DIF) study of perilesional skin there was linear deposition of C3 and IgG in dermoepidermal junction. Therefore the diagnosis of bullous pemphigoid was confirmed. In CBDC the DIF finding is linear deposition of IgA at dermoepidermal junction so it was not a case of CBDC. In DH granular deposition of IgA in dermal papilla is the confirmatory findings of DIF so it was not a case of DH.

Final diagnosis of both the author:

Infantile bullous pemphigoid

Discussion

Bullous pemphigoid represents almost two third of all subepidermal autoimmune bullous diseases. The yearly incidence of BP is 2.5 to 42.8/million in a recent study.⁹ Infantile bullous pemphigoid is a very rare variant of BP. The first case report of infantile BP was published in 1977. From 1977 to 2013 only 81 cases was reported worldwide. In a study incidence of infantile BP was found 2.36 per 100,000 in one year.¹⁰

The histopathological and immunopathological characteristics of BP in adults and in infants are similar. However, some variations are found in infantile BP such as palmoplantar involvement, course of disease is benign, lower recurrence rate and prognosis is better than that of adult type.^{11,12,13}

Aim of our presentation was to describe a case of infantile BP, a very rare variant of BP and brought Tzanck test to light. Tzanck test is also known as cytodiagnosis that depends on cytology of single cell. George Papanicolaou was the pioneer of practicing the method of exfoliative cytology. In dermatological diagnosis Arnault Tzanck started the era of cytology in 1947 in pemphigus vulgaris and herpes viral infections. Later this test was named as Tzanck test or "Tzanck smear" and was using as a diagnostic tool in dermatology. Tzanck test was proved valuable in diagnosis and differentiation of autoimmune bullous diseases, Stevens Jhonson syndrome SJS/TEN and herpes virus infections.^{14,15}

Tzanck test is a rapid, inexpensive, non-invasive bed side test. In case of bullous pemphigoid and other autoimmune bullous diseases DIF test is the gold standard and confirmatory test but it is expensive, time consuming and only available in few specialized centers in Bangladesh. It is hard to afford and reached to the center from outside of the capital city during the COVID-19 pandemic. Bullous dermatoses like BP and pemphigus vulgaris (PV) are the dermatological emergency and in most of the time patients require early diagnosis and treatment. Tzanck test can be an easier diagnostic aid in taking decision for some patients in some life threatening conditions. By Tzanck test pemphigus vulgaris (PV) can be diagnosed by identifying the Tzanck cell, large rounded acantholytic keratinocytes from the base of bullae and the test specificity is almost 100% like DIF. In BP detection of eosinophil in Tzanck smear showed 100% specificity in different studies. Though the sensitivity Tzanck test is variable and investigator dependent the results is comparable and to histopathology and DIF study. In dermatitis herpetiformis presence of neutrophil in bullae in Tzanck test the specificity of the report is 100%. The presence of mite in Tzanck smear is diagnostic for bullous scabies and presence of bacteria and neutrophil is specific finding for bullous impetigo.^{16,17,18,19}

Conclusion

Typical clinical features and presence of eosinophil in Tzanck smear can be an aid to confirm the diagnosis of infantile BP where the facility of histopathology and DIF test is unavailable.

References

1. Patsatsi A. Chronic bullous disease or linear IgA dermatosis of childhood – revisited. *J Genet Syndr Gene Ther.* 2013;4(6):1-5.
2. Han JH, Yun SJ, Kim SJ, Lee SC, Won YH, Lee JB. A Case of Chronic Bullous Disease of Childhood That Was Reactive to the Antigen of 120 kDa (LAD-1). *Ann Dermatol.* 2011 ;23(2):209-212.
3. Chorzelski TP, Jablonska S. IgA linear dermatosis of childhood (chronic bullous disease of childhood). *British Journal of Dermatology.* 1979;101(5):535-42.
4. Templet JT, Welsh JP, Cusack CA. Childhood dermatitis herpetiformis: a case report and review of the literature. *Cutis.* 2007;80(6):473-6.
5. Powell GR, Bruckner AL, Weston WL. Dermatitis herpetiformis presenting as chronic urticaria. *Pediatric dermatology.* 2004;21(5):564-7.
6. Antiga E, Maglie R, Quintarelli L, Verdelli A, Bonciani D, Bonciolini V et al. Dermatitis herpetiformis: novel perspectives. *Frontiers in immunology.* 2019;10:1290.
7. Bardhan A, Bruckner-Tuderman L, Chapple IL, Fine JD, Harper N, Has C et al. *Nature Reviews Disease Primers.* 2020 Sep 24;6(1):1-27.
8. Has C, Bauer JW, Bodemer C, Bolling MC, Bruckner-Tuderman L, Diem A et al. Consensus reclassification of inherited epidermolysis bullosa and other disorders with skin fragility. *British Journal of Dermatology.* 2020;183(4):614-27.
9. Aoki V, Miyamoto D. Unfolding the worldwide incidence of bullous pemphigoid: what are we missing? *British Journal of Dermatology.* 2021 Nov 22.
10. Schwieger-Briel A, Moellmann C, Mattulat B, Schauer F, Kiritsi D, Schmidt E et al. Bullous pemphigoid in infants: characteristics, diagnosis and treatment. *Orphanet journal of rare diseases.* 2014;9(1):1-2.
11. Barreau M, Stefan A, Brouard J, Leconte C, Morice C, Comoz F et al. Infantile bullous pemphigoid. *Annales de Dermatologie et de Venereologie;* 2012;139: 555-8.
12. Sousa B, Mota A, Morgado H, Lopes JM, Dias JA. Bullous pemphigoid in an infant. *Actamedicaportuguesa.* 2005; 18(2): 159-62.
13. Reis-Filho EG, Silva TD, Aguirre LH, Reis CM. Bullous pemphigoid in a 3-month-old infant: case report and literature review of this dermatosis in childhood. *Anaisbrasileiros de dermatologia.* 2013; 88:961-5.

14. Durdu M, Seçkin D, Baba M. The Tzanck smear test: Rediscovery of a practical diagnostic tool. *Skinmed*. 2011;9:23-32.
15. Eryilmaz A, Durdu M, Baba M, Yildirim FE. Diagnostic reliability of the Tzanck smear in dermatologic diseases. *Int J Dermatol*. 2014;5(3):178-86.
16. Mokhtari M, Rasolmali R, Kumar PV. Pemphigus vulgaris of skin: cytological findings and pitfalls. *Acta cytologica*. 2012;56(3):310-4.
17. Durdu M, Baba M, Seçkin D. The value of Tzanck smear test in diagnosis of erosive, vesicular, bullous, and pustular skin lesions. *Journal of the American Academy of Dermatology*. 2008 ;59(6):958-64.
18. Aneesh S , Raghavendra B, Aaryambika K, Patra A K, Bijina K, Comparison of the diagnostic efficacy of Tzanck smear with histopathology and direct immunofluorescence in immunobullous disorders. *IP Indian J Clin Exp Dermatol*. 2019;5(3):211-215.
19. Yaeen A, Ahmad QM, Farhana A, Shah P, Hassan I. Diagnostic value of Tzanck smear in various erosive, vesicular, and bullous skin lesions. *Indian Dermatol Online J*. 2015 ;6(6):381-6.